



# Asymptomatic Preoperative Leukocytosis and Salivary Gland Excision Clinical Outcomes

Sugosh M. Anur, BS<sup>1</sup>; Rushi Patel, MD<sup>2</sup>; Prayag Patel, MD<sup>2</sup>; Jean Anderson Eloy, MD, FACS<sup>2</sup>

<sup>1</sup>Rowan University School of Osteopathic Medicine, <sup>2</sup>Rutgers New Jersey Medical School – Department of Otolaryngology – Head and Neck Surgery

## ABSTRACT

**Objective:** An increase in white blood cell (WBC) count can indicate the presence of infection, inflammation, or immune disorder. Some patients may have elevated WBC counts without any symptoms. The objective of this study is to determine association between asymptomatic leukocytosis with postoperative outcomes following salivary gland excision (SGE).

**Study Design:** Retrospective database study.

**Methods:** The 2005-2018 National Surgical Quality Improvement Program database was queried for all patients undergoing SGE. Patients with preoperative sepsis, septic shock, pneumonia, wound infection, disseminated cancer, renal failure, and history of chronic steroid use were excluded. Cases were grouped into leukocytosis ( $\geq 11k/\mu L$ ) or normal WBC ( $<11k/\mu L$ ). Univariate and multivariate analyses were performed.

**Results:** A total of 18,416 patients underwent salivary gland excision, of which 12,553 patients had valid preoperative WBC values. 664 patients (5.29%) had preoperative leukocytosis. Adjusting for confounding variables, multivariate regression analysis showed association between leukocytosis and all postoperative complications (OR: 2.084 (1.604-2.707),  $p < 0.01$ ). Specifically, leukocytosis was significantly associated with superficial surgical site infection (OR: 2.304 (1.523-3.485),  $p < 0.001$ ), pneumonia (OR: 3.552 (1.863-6.775),  $p < 0.01$ ), bleeding transfusion (OR: 2.432 (1.580-3.741),  $p < 0.01$ ), and DVT requiring therapy (OR: 6.269 (1.734-22.665),  $p = 0.005$ ).

**Conclusions:** Our study demonstrates that patients with preoperative asymptomatic leukocytosis are at risk of experiencing postoperative complications. Elevated WBC count in asymptomatic patients could indicate need for increased monitoring.

## CONTACT

Jean Anderson Eloy, MD, FACS  
Rutgers New Jersey Medical School  
Department of Otolaryngology-Head and Neck Surgery  
185 S Orange Ave, Newark, 07103  
eloyj1@njms.Rutgers.edu

## INTRODUCTION

- Increased white blood cell count can indicate the presence of an infection, inflammation, or immune system disorder. There has been a strong association between asymptomatic leukocytosis and preoperative dehydration and abnormal albumin levels. Additionally, studies show that the risk of postoperative ventilator dependence and unplanned intubation increases in the presence of asymptomatic leukocytosis.<sup>1</sup>
- Literature exploring the association of asymptomatic leukocytosis and postoperative complications exists in cardiac and general surgical procedures.<sup>1,2</sup> However, there is dearth of studies exploring procedures in otolaryngology.
- Although salivary gland excision is a common procedure and has low rates of adverse outcomes due to the improvement in surgical training and technology, complications include bleeding, infection, facial nerve damage, salivary fistula formation, and gustatory sweating.<sup>3</sup>
- The purpose of this study is to assess the association of an elevated white blood cell count in patients without symptoms of infection, inflammation, or immune disorders.

## METHODS AND MATERIALS

The 2005-2018 National Surgical Quality Improvement Program database was queried for all patients undergoing SGE. Cases were selected for salivary gland excision based on the following current procedural terminology codes: 42410, 42415, 42420, 42425, 42426, 42440, and 42450. Patients with preoperative sepsis, septic shock, pneumonia, wound infection, disseminated cancer, renal failure, and history of chronic steroid use were excluded. Cases were grouped into leukocytosis ( $\geq 11k/\mu L$ ) or normal WBC ( $<11k/\mu L$ ). Complications included postoperative pneumonia, reintubation, acute renal failure, urinary tract infection, cardiac arrest, bleeding transfusion, myocardial infarction, sepsis, and *C. difficile* infection. Clotting complication included development of deep vein thrombosis (DVT) or pulmonary embolism (PE). Univariable chi square analysis, independent sample t-test, and multivariable logistic regression were performed appropriately using the SPSS software.

## RESULTS

- Sample Size: 18,416 patients
- Valid WBC Count: 12,553 patients
- Asymptomatic Preoperative Leukocytosis: 664 (5.3%) patients

Figure 1. Chi Square Analysis of White Blood Cell Count and All Complications

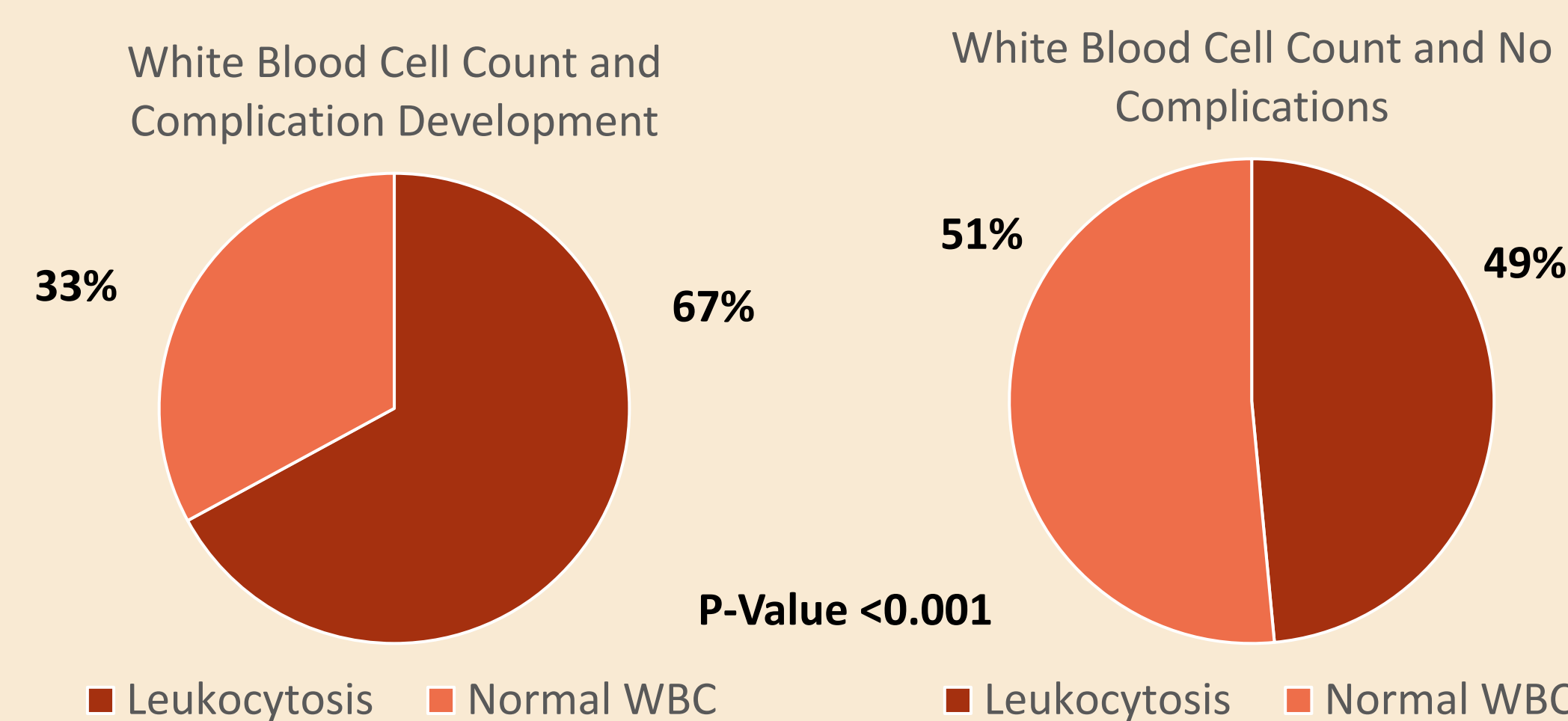


Figure 1. Chi Square Analysis of White Blood Cell Count and Individual Postoperative Complications

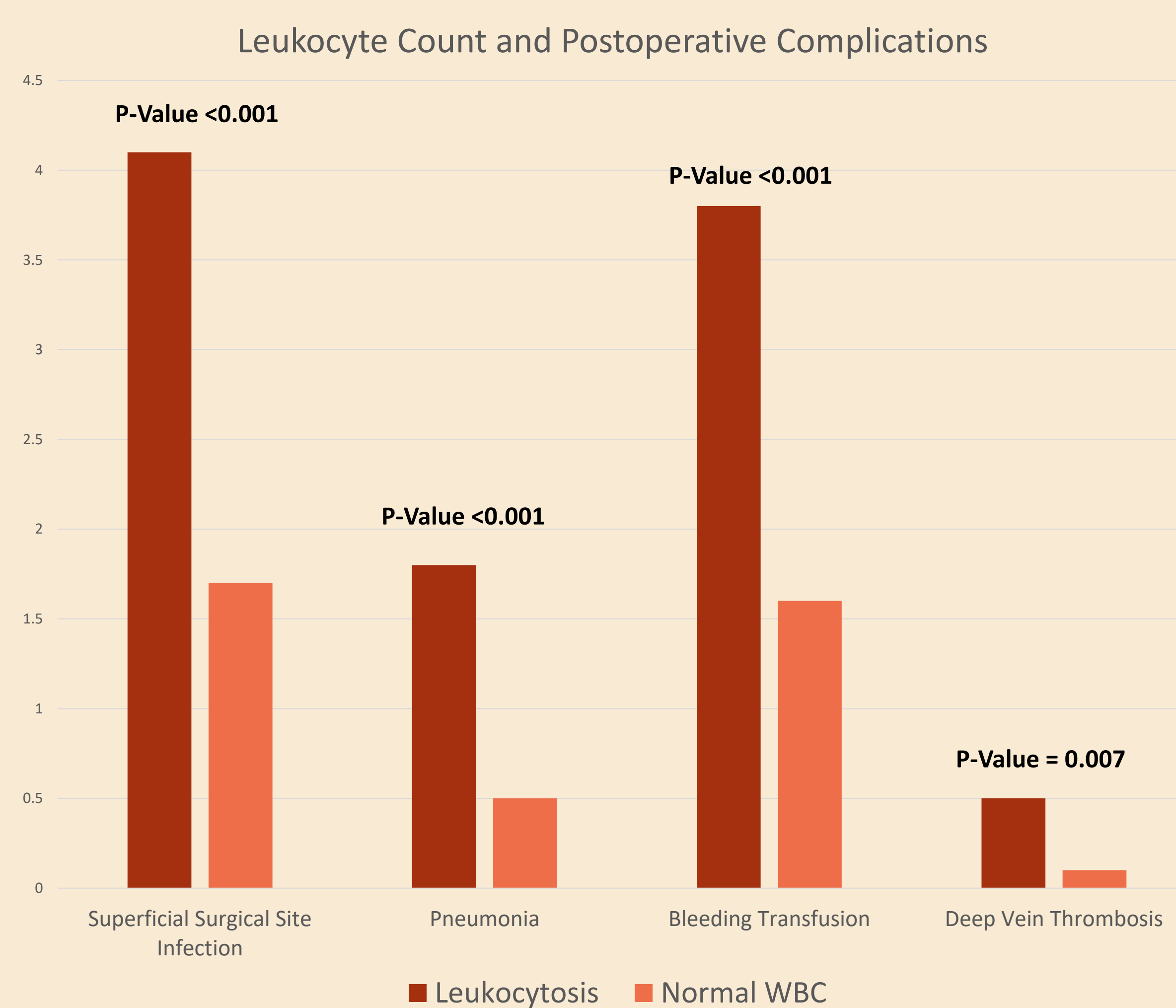


Table 1. Multivariable Regression of Leukocytosis as an Independent Predictor

Variable	OR	95% CI	P-Value
All Complications	2.084	1.604 – 2.707	<0.001
Surgical Complications			
Superficial Surgical Site Infection	2.304	1.523 – 3.485	<0.001
Medical Complications			
Pneumonia	3.552	1.863 – 6.775	<0.001
Bleeding Transfusion	2.432	1.580 – 3.471	<0.001
DVT Requiring Therapy	6.269	1.734 – 22.665	0.005

## DISCUSSION

- Leukocytosis was associated with all complications, especially superficial surgical site infection, pneumonia, bleeding transfusion, and deep vein thrombosis.
- These findings are similar to literature examining preoperative leukocytosis in cardiac surgery.<sup>1</sup> It is plausible that the presence of leukocytosis represents subclinical inflammation and therefore the trauma of surgery overwhelms the ability to maintain an immunocompetent state, leading to infection and pneumonia.
- We found that blood transfusions were associated with preoperative asymptomatic leukocytosis. A plausible explanation is these patients may have been dehydrated prior to surgery, and a bleeding complication in these patients exacerbates the need for a blood transfusion. Studies have shown the increased association between asymptomatic leukocytosis and dehydration<sup>4,6</sup>. Additionally, studies have shown association with poor nutrition index.
- Future studies can analyze malnutrition by assessing albumin values in patients with asymptomatic leukocytosis undergoing head and neck procedures.

## CONCLUSIONS

Our study demonstrates that patients with preoperative asymptomatic leukocytosis are at risk of experiencing postoperative complications. Consideration to monitor patients with elevated WBC count in asymptomatic patients prior to operating may be considered. Future studies examining impact of malnutrition may provide better answers.

## REFERENCES

- Mahmood E, Knio ZO, Mahmood F, et al. Preoperative asymptomatic leukocytosis and postoperative outcome in cardiac surgery patients. *PLoS One*. 2017;12(9):e0182118. Published 2017 Sep 5. doi:10.1371/journal.pone.0182118
- Sagi HC, Dziadosz D, Mir H, Virani N, Olson C. Obesity, leukocytosis, embolization, and injury severity increase the risk for deep postoperative wound infection after pelvic and acetabular surgery. *J Orthop Trauma*. 2013;27: 6–10. doi: 10.1097/BOT.0b013e31825cf382
- Powell ME, Clairmont AA. Complications of parotidectomy. *South Med J*. 1983;76(9):1109-1112. doi:10.1097/00007611-198309000-00010
- Tibaldi C, Vasile E, Bernardini I, et al. Baseline elevated leukocyte count in peripheral blood is associated with poor survival in patients with advanced non-small cell lung cancer: a prognostic model. *J Cancer Res Clin Oncol* 2008;134:1143e1149
- Mank V, Azhar W, Brown K. Leukocytosis. [Updated 2023 Mar 12]. In: StatPearls [Internet]. Treasure Island (FL): StatPearls Publishing; 2023 Jan-. Available from: <https://www.ncbi.nlm.nih.gov/books/NBK560882>
- Monreal M, Fernandez-Llamazares J, Pinol M, et al. Platelet count and survival in patients with colorectal cancer: a preliminary study. *Thromb Haemost* 1998;79: 916e918.