



Malleus Head Fixation: Clinical Exam Demonstration and Systematic Management Approach

Douglas J. Totten, MD, MBA,¹ Evan Cumpston, MD,¹ Rick F. Nelson, MD, PhD^{1,2}¹Department of Otolaryngology—Head & Neck Surgery; ²Department of Neurological Surgery, Indiana University, IN, USA

Objective

To demonstrate how malleus head fixation may be reliably identified on physical exam and discuss a safe, efficient, and effective approach to surgical management.

Introduction

Malleus head fixation results in conductive hearing loss (CHL) that has overlapping audiologic finding to otosclerosis making it difficult to diagnose. To our knowledge, no prior research has documented a systematic approach to the workup of patients with suspected malleus head fixation. This study describes five cases of malleus head fixation, postoperative outcomes, and proposes a systematic approach to patient workup and management.

Methods

Patients diagnosed with malleus head fixation from 2018-2023 were included in this study. Presenting symptoms, past surgical and otologic history, radiographic findings, operative records, and pre- and post-operative pure tone average (PTA) of 0.5, 1, 2 and 3 kHz were recorded.

Figure 1. CT example of Malleus Head Fixation

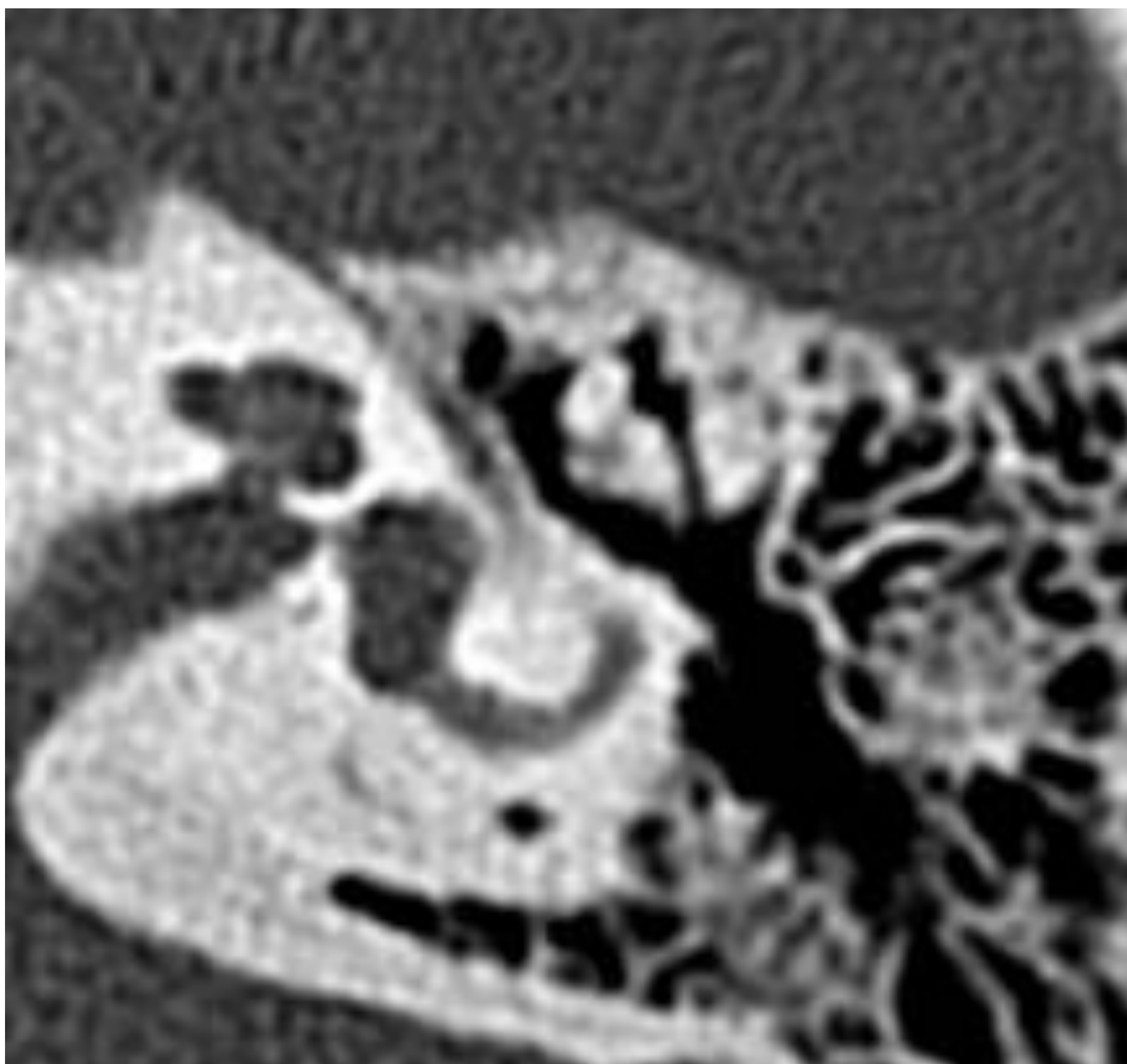


Table 1. Patient characteristics, physical exam and imaging findings, and hearing improvement post-operatively. Pt: Patient, ID: Identification number, CT: computed tomography, ABG: Air-bone gap

Pt ID	Age	Gender	Pneumatic Otoscopy Findings	CT Finding	Pre-Op ABG	Post-Op ABG
1	48	Male	Attic retraction	Not identified; Found Intra-Op	26	6
2	55	Female	Malleus Immobile	Malleus Fixation, no otosclerosis	22	9
3	46	Female	Malleus Immobile	Malleus Fixation, no otosclerosis	14	7
4	61	Female	Malleus Immobile	Malleus Fixation, no otosclerosis	26	21
5	55	Female	Malleus Immobile	Malleus Fixation, no otosclerosis	25	4

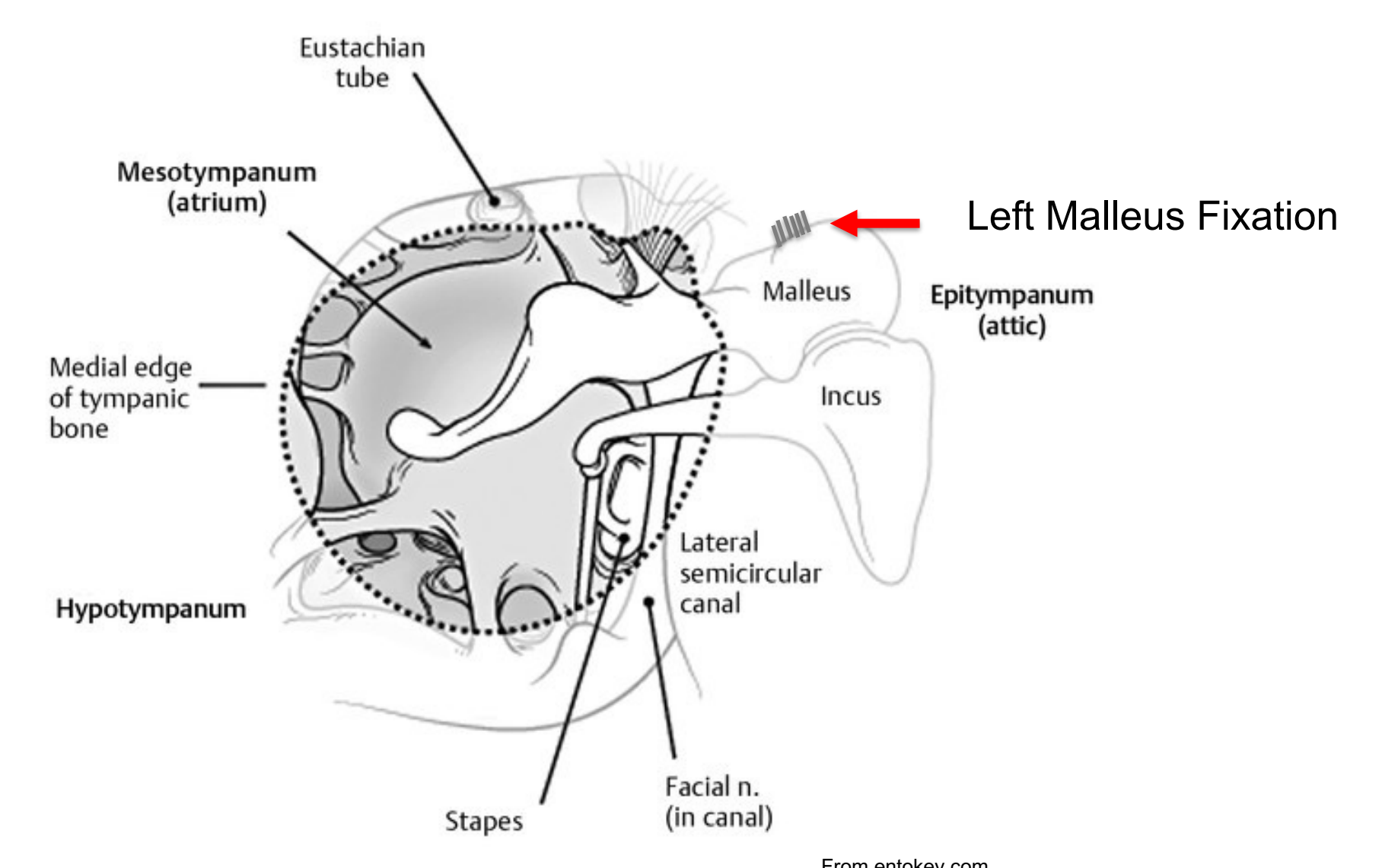
Results

Five patients diagnosed with malleus head fixation underwent ossicular chain reconstruction. Four were female. Average age was 53 (standard deviation: 6) years. All patients presented with a prolonged history of hearing loss and had absent acoustic reflexes pre-operatively. Four patients had documented malleus head immobility on pneumatic otoscopy and pre-operative imaging demonstrating malleus head fixation in all cases. One patient with suspected otosclerosis had malleus head fixation noted intraoperatively. All patients were treated with endaural atticotomy with laser for mobilization. Four patients experienced subjective hearing improvement while one patient's outcome was complicated by additional middle ear pathology. The pre-operative PTA air-bone gap (ABG) improved from 22.5 dB to 9.4 dB post-operatively with a mean improvement in ABG of 13.1 dB ($p=0.008$).

Table 2. Assessment of etiology of conductive hearing loss

	Acoustic Reflex	Mobility on Pneumatic Otoscopy	512 Rinne Test
Malleus Head Fixation	+	-	-
Otosclerosis	+	+	-
SSCD	+	+	+

Figure 2. Diagram of left malleus head fixation



Discussion

Malleus head fixation is a relatively rare pathology that may often be confused with otosclerosis due to similar audiometric findings including CHL and Type A tympanometry, and absent acoustic reflexes. If malleus immobility is not noted pre-operatively in clinic and no imaging has been performed, patients may undergo an unnecessary procedure without clinical benefit. Consequently, it is imperative for the otolaryngologist to include malleus head fixation on all patients with CHL absent acoustic reflexes, and/or presumed otosclerosis. Furthermore, the otolaryngologist should be able to evaluate and reliably recognize malleus immobility based on clinical examination. We present still images from videos (see supplemental material for full videos) demonstrating reliable technique for diagnosing malleus head fixation.

Conclusion

While rare, CHL from malleus head fixation presents with absent acoustic reflexes and may be reliably detected with pre-operative pneumatic otoscopy. In any patient with suspected otosclerosis, pneumatic otoscopy should be used to evaluate malleus mobility. Imaging may subsequently be performed to confirm malleus fixation.

CONTACT

Rick Nelson, MD, PhD
ricnelso@iupui.edu

REFERENCES

- Fernandez JJ, Botti C, Fermi M, Presutti L. Endoscopic Management of Malleus Head Fixation in Revision Stapes Surgery. *Otol Neurotol*. 2020 Jun;41(5):614-617. doi: 10.1097/MAO.0000000000002592. PMID: 32080028.
- Crutcher WL, Tassone P, Pelosi S. Ossicular chain mobilisation versus reconstruction in surgery for isolated malleus and/or incus fixation: systematic review and meta-analysis. *J Laryngol Otol*. 2018 Oct;132(10):858-865. doi: 10.1017/S0022215118001494. Epub 2018 Oct 5. PMID: 30289092.
- Motegi M, Yamamoto Y, Akutsu T, Tada T, Kurihara S, Takahashi M, Sempel S, Morino T, Yamamoto K, Sakurai Y, Kojima H. Radiological and Audiological Prediction for Ossicular Fixation in Chronic Otitis Media and Tympanic Membrane Perforation. *Otol Neurotol*. 2022 Jan 1;43(1):80-89. doi: 10.1097/MAO.0000000000003346. PMID: 34510119.
- Lundman L, Strömback K, Björnsne A, Grendin J, Dahlin-Redfors Y. Otosclerosis revision surgery in Sweden: hearing outcome, predictive factors and complications. *Eur Arch Otorhinolaryngol*. 2020 Jan;277(1):19-29. doi: 10.1007/s00405-019-05652-w. Epub 2019 Sep 23. PMID: 31549194.
- Zhan KY, Mattingly JK, Adunka OF. Isolated malleus fixation: A pediatric case series. *Int J Pediatr Otorhinolaryngol*. 2019 Sep;124:1-5. doi: 10.1016/j.ijporl.2019.05.021. Epub 2019 May 22. PMID: 31136915.