

Case Series: Epistaxis Requiring Embolization After RhinAer

Randy W. Lesh, MD¹, Hassan Paknezhad, MD²

¹Geisinger Medical Center, Danville, PA

²Geisinger Wyoming Valley Medical Center, Wilkes-Barre, PA

Geisinger

Background

- Chronic rhinitis (CR) is resistant to medical therapy in 10-22% of cases.
- FDA approved in 2020, radiofrequency neurolysis of the posterior nasal nerve (PNN) (RhinAer) may be used to treat CR.
- Vidian neurectomy was previously used but it carried the risk of cheek/palate numbness and dry eye.
- RhinAer targets the post-ganglionic PNN branches of the vidian nerve as they exit the sphenopalatine foramen.
- The wand is placed near the posterior middle meatus and superior-posterior inferior turbinate.
- Device monitors tissue temperature and adjusts radiofrequency to maintain approximately 60° C.
- Procedure has demonstrated significant and sustained reduction in CR symptoms through 24 months.
- Good safety profile with no events raising concerns in clinical trial.

References

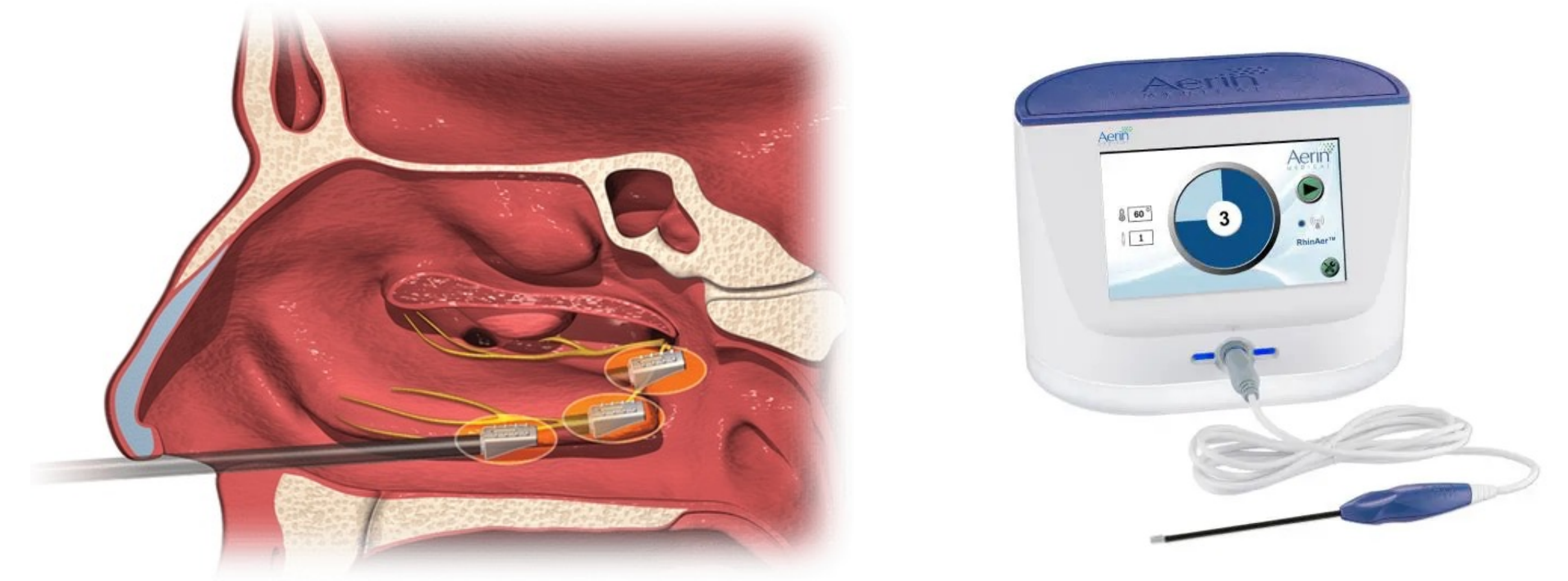
1. Yu AJ, Tam B, Wröbel B, Hur K. Radiofrequency Neurolysis of the Posterior Nasal Nerve: A Systematic Review and Meta-Analysis. *Laryngoscope*. 2023 Jul 29. doi: 10.1002/lary.30911. Epub ahead of print. PMID: 37515507.
2. Stolovitzky JP, Ow RA, Silvers SL, Bikhazi NB, Johnson CD, Takashima M. Effect of Radiofrequency Neurolysis on the Symptoms of Chronic Rhinitis: A Randomized Controlled Trial. *OTO Open*. 2021 Sep 10;5(3):2473974X211041124. doi: 10.1177/2473974X211041124. PMID: 34527852; PMCID: PMC8436321.
3. Takashima M, Stolovitzky JP, Ow RA, Silvers SL, Bikhazi NB, Johnson CD. Temperature-controlled radiofrequency neurolysis for treatment of chronic rhinitis: 12-month outcomes after treatment in a randomized controlled trial. *Int Forum Allergy Rhinol*. 2023 Feb;13(2):107-115. doi: 10.1002/alr.23047. Epub 2022 Jul 5. PMID: 35714267; PMCID: PMC10083967.
4. FDA Approval 2020, RhinAer (Aerin Medical)

Case 1

A 37-year-old woman with longstanding history of CR and nasal bone fracture s/p multiple functional endoscopic sinus surgeries and septoplasty x3 presented to the ED with severe bilateral epistaxis 12 days after temperature-controlled radiofrequency neurolysis of the PNN (RhinAer) by an outside otolaryngologist. She reported onset of epistaxis after bending down to lift her child. Bilateral anterior and posterior nasal packing stopped the active bleeding, and the patient was admitted to the ICU. She had three episodes of recurrent epistaxis despite nasal packing. Her hemoglobin dropped from 11.6 g/dL at admission to 7.3 g/dL. The patient was transfused with two units of PRBCs and emergently taken to the OR for coil embolization of bilateral sphenopalatine (SPA) and internal maxillary (IMA) arteries. On POD #1, she received an additional unit of PRBC for symptomatic anemia. She was discharged home with nasal saline spray. The patient had no epistaxis, nasal crusting, or nasal dryness at 4 month follow up at our institution, however reported intermittent mild epistaxis and dry nasal crusting at 8 month follow up at an outside hospital.

Case 2

A 57-year-old man with history of CR presented with epistaxis following RhinAer by an outside otolaryngologist. He was seen at an outside ED shortly after the procedure for epistaxis and treated with nasal cautery and packing. The patient denied anticoagulant use. He continued to have epistaxis and a rhinorocket was placed in his surgeon's office. He presented to the ED several days later with bleeding from the right naris. Hgb on presentation was 10.7 g/dL. Packing was removed and he had no active bleeding, however there was evidence of recent epistaxis. Merocel packing was placed, and he was admitted for observation. He was discharged home the following day. Three days later he presented to the ED with right sided epistaxis. The merocel packing was removed to reveal brisk bleeding. Bleeding was temporizing with NasoPore packing. Hgb at this time was 8.5 g/dL. CTA head/neck did not show active extravasation.



He underwent embolization of the right sphenopalatine and angular arteries. During the procedure, vascular blush was noted in bilateral sphenopalatine areas and right angular artery. His Hgb was 7.3 g/dL on POD #1, and he did not receive a blood transfusion. He had no further epistaxis and was discharged home on POD #1. The patient was seen in follow up on POD #8 and denied epistaxis since embolization. He was seen in follow up with neurosurgery one month postoperatively and reported olfactory dysfunction but continued to be free of epistaxis.

Conclusion

- RhinAer has demonstrated effectiveness in treating CR
- No major safety concerns in clinical trial and just 3 cases of epistaxis cited in recent meta-analysis (Yu et al.)
- We present two cases of severe epistaxis requiring coil embolization
- Anatomic variation of the SPA may have predisposed these patients to post-procedure epistaxis
- Otolaryngologists should be aware of the potential for complications after RhinAer
- Consider an interval between treating each PNN