

Enhancing Wound Bed Preparation, Combining Bacterial Load Imaging Detection Technology with a Pure Hypochlorous Acid Preserved (pHA)* Cleanser

Dot Weir, RN, CWON, CWS¹

1. Saratoga Hospital Center for Wound Healing and Hyperbaric Medicine, Saratoga Springs, New York

INTRODUCTION

Wound healing can be aided by utilizing the concept of “wound hygiene” at every dressing change. This consists of appropriate cleansing with non-cytotoxic agents that have evidence-based bioburden removal properties, debriding when needed and appropriate with attention to the wound edge, and management with dressings based on a thorough wound assessment.

We have found our wound bed preparation steps to be optimally enabled and enhanced using an imaging device** that detects bacterial load and its locations. We use this imaging guidance to help us to target our cleansing, and ultrasound mechanical and sharp debridement procedures while always utilizing a hypochlorous acid (HOCl) preserved cleanser and observing serial images to confirm the removal of bacteria via image-based targeting. We have found that this judicious and continuous use of our HOCl cleansing agent confirms the effectiveness of the practice, validating that we don't need to use caustic/toxic agents such as Dakin's solution or povidone iodine purely to achieve dramatic pre- and post- procedure images. We can confirm the reduction in bacterial load required to promote continued wound repair with the less cytotoxic HOCl-based cleanser.

METHODS

We imaged for bacterial load pre and post wound cleansing. We present pre/post cleansing images on complex wounds with depth/crevices. Cleansing is typically done by irrigating wound spaces/tracts, soaking the wound bed with the gauze fully soaked with the cleanser, followed by vigorous scrubbing of the wound when needed and tolerated. Lidocaine gel can be used as needed. No rinsing is necessary for HOCl based cleansers.

RESULTS

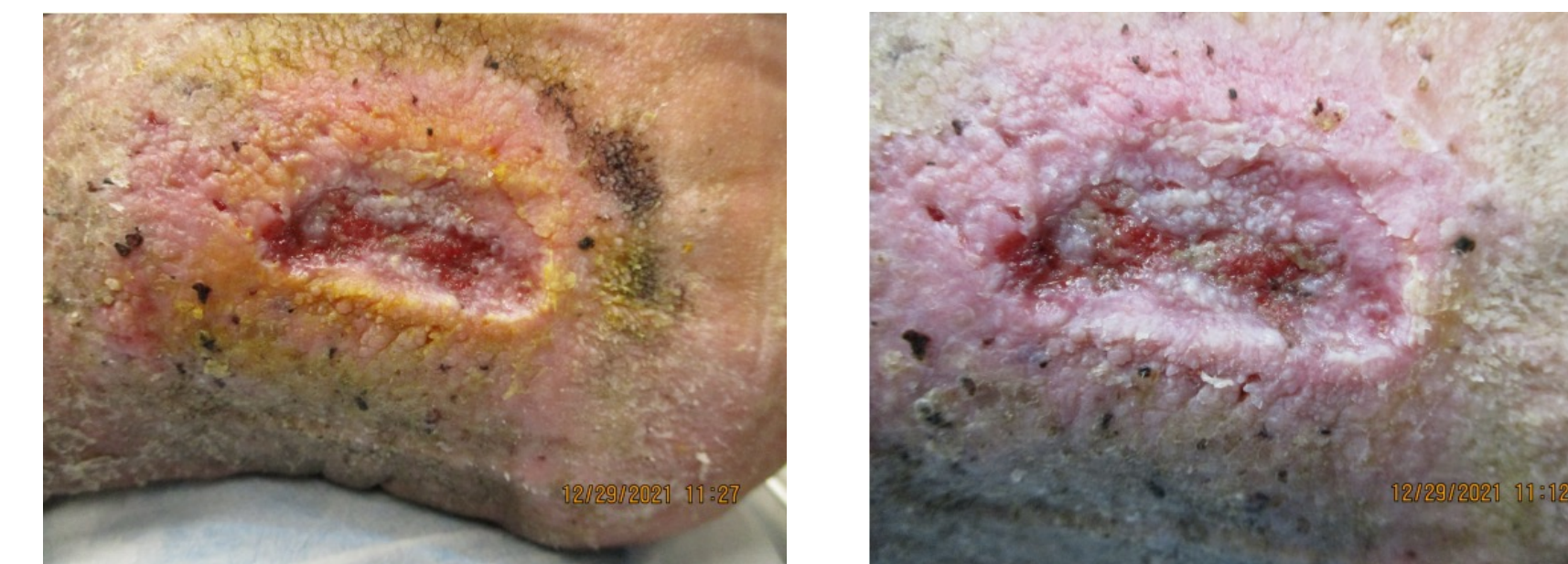
We have noted that chronic wounds invariably have a high bioburden not only often in the wound bed, but also the periwound skin, and especially so if the skin has become macerated. Effective mechanical cleansing and debridement with a safe antimicrobially preserved cleanser agent that can be used throughout the wound healing process has dramatically aided in our bioburden control. Post debridement, remnant bioburden and periwound bioburden is efficiently removed with a pure Hypochlorous Acid based cleanser, over several consecutive sessions of wound bed preparation. Both soaking and mechanical scrubbing of the wound/periwound with gauze is essential to obtain optimal bacterial removal. Imaging of gauze used for cleansing reveals large quantities of removed bacteria in the cleansing step.

CONCLUSION

Wound healing happens is improved when effective wound hygiene is practiced. Imagery shows bacterial load removal with HOCl based cleanser is effective, but also suggests that wound hygiene requires repetitive cleansing with mechanical scrubbing during cleansing. The battle to conquer bacteria in the wound requires constant vigilance and diligence via repetitive steps that gradually bring bacterial levels under control.

CASES

CASE 1



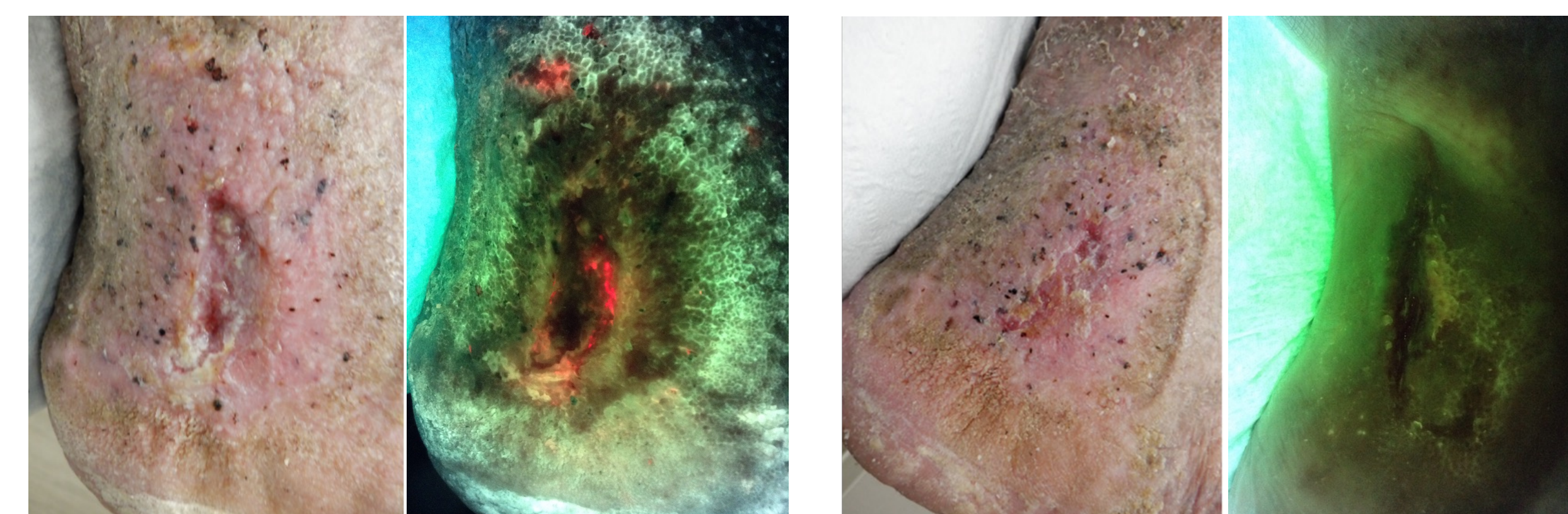
Initial gauze cleansing



Before cleansing

During cleansing

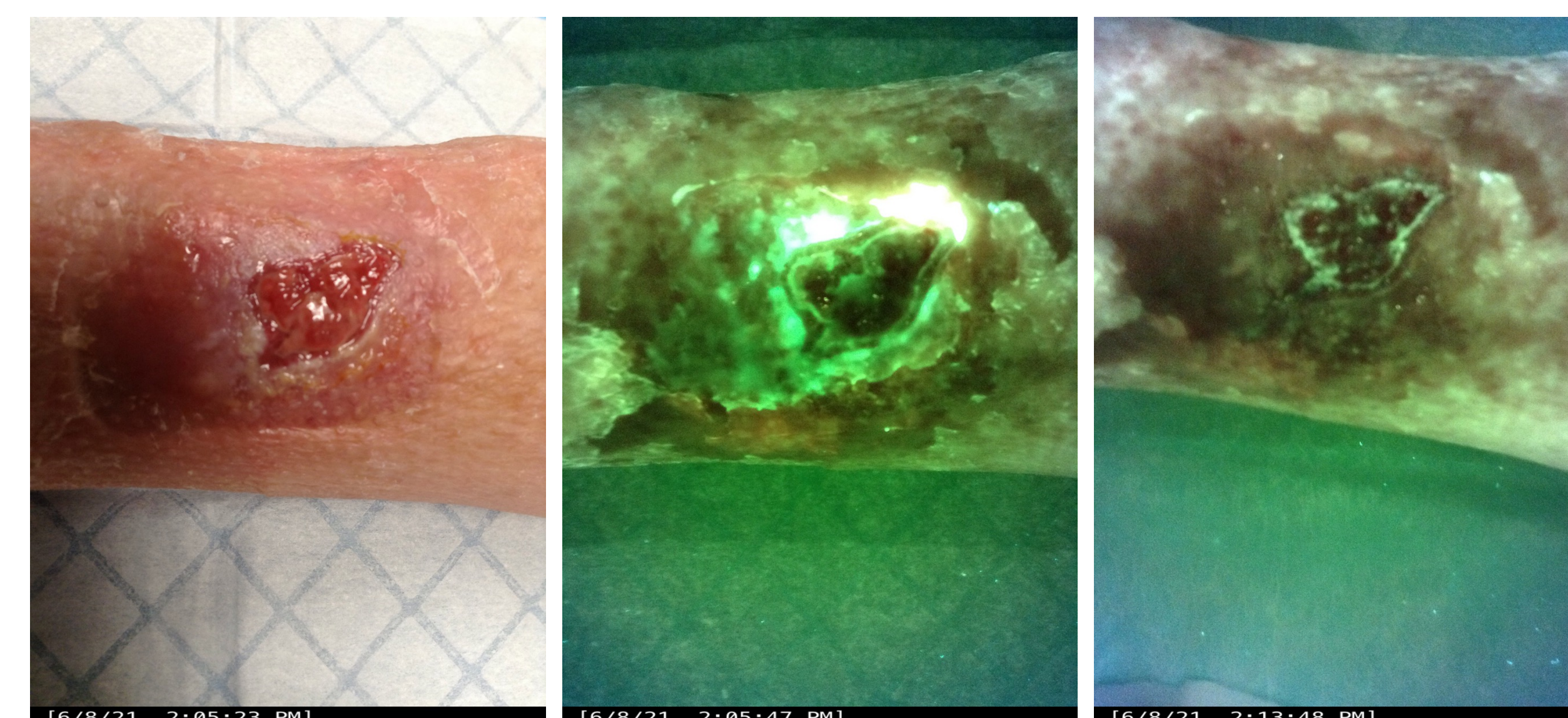
After cleansing



Day 7

Day 20

CASE 2

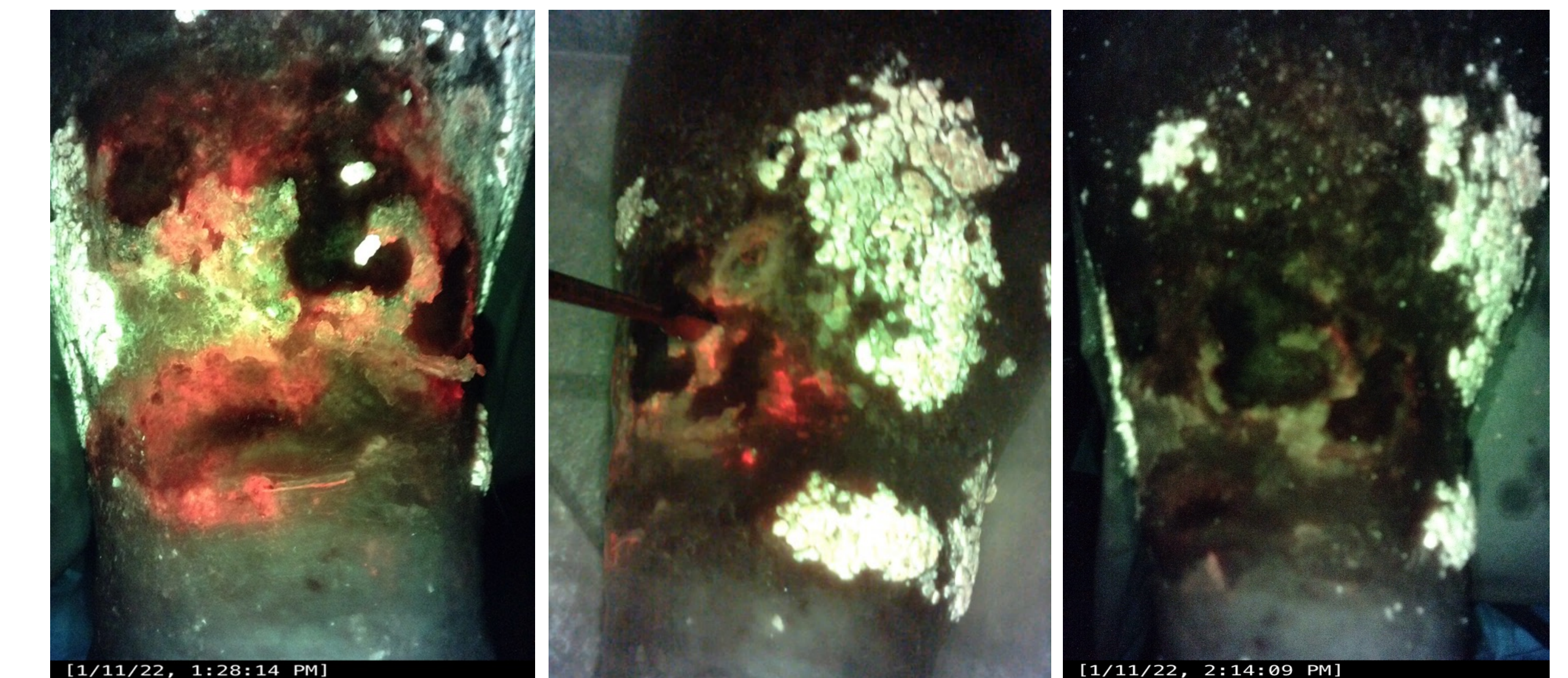


Before cleansing

Before cleansing

After cleansing

CASE 3 - ULTRASONIC DEBRIDEMENT WITH PHA CLEANSER UNDER FLUORESCENCE IMAGING

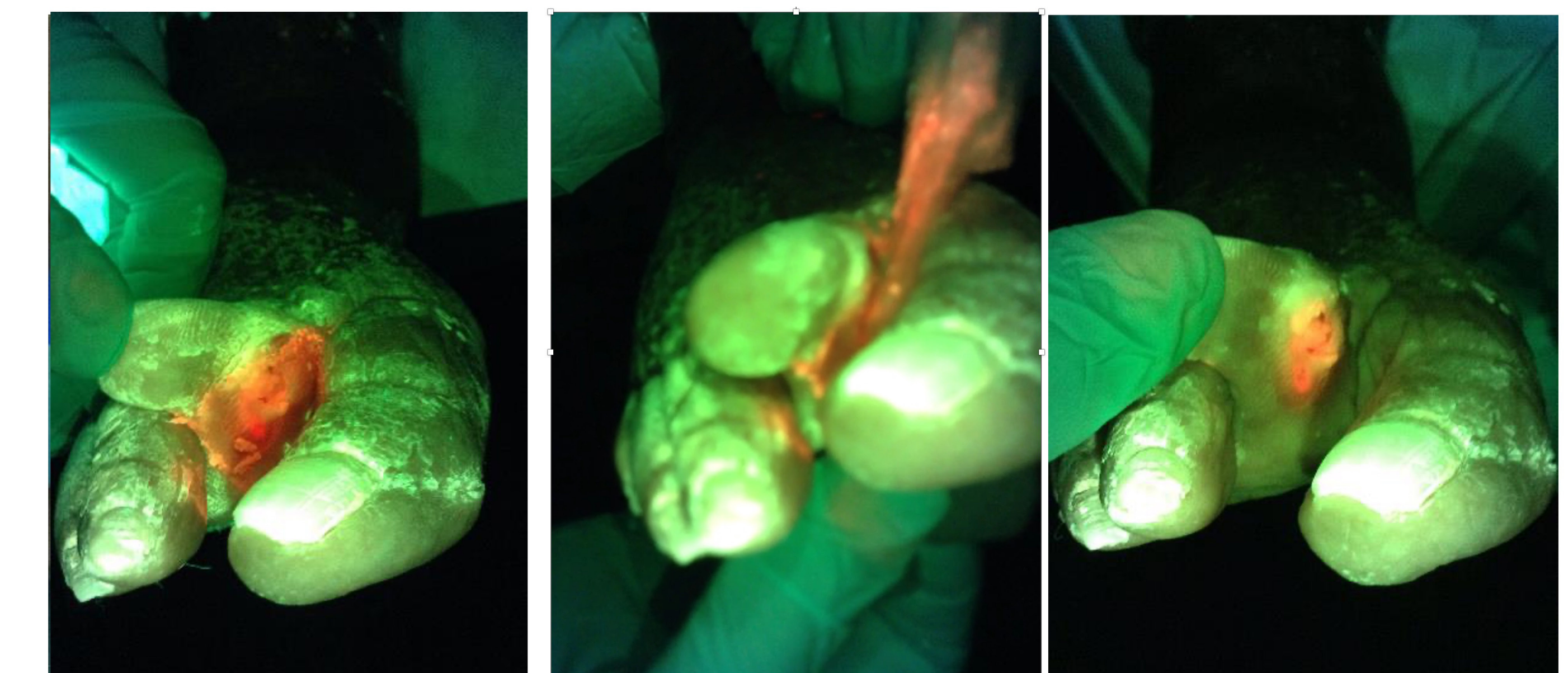


Before cleansing

During cleansing

After cleansing

CASE 4 - TOE FLOSSING, REMOVING GERMS IN WOUND BETWEEN THE TOES



Before cleansing

During cleansing

After cleansing

REFERENCES

- Murphy C, Atkin L, Swanson T, et al. Defying hard-to-heal wounds with an early antibiofilm intervention strategy: wound hygiene. *J Wound Care*. 2020 Mar 1;29(Sup3b):S1-S26
- Armstrong DG, Bohn G, Glat P, Kavros SJ, Kirsner R, Snyder R, Tettelbach W, Armstrong DG, et al. Expert Recommendations for the Use of Hypochlorous Solution: Science and Clinical Application. *Ostomy Wound Management* 2015 May;61(5): S2-S19.
- Block, Michael S, and Brian G Rowan. "Hypochlorous Acid: A Review." *Journal of oral and maxillofacial surgery : official journal of the American Association of Oral and Maxillofacial Surgeons* vol. 78,9 (2020): 1461-1466.
- Dissemond J. Wound cleansing: benefits of hypochlorous acid. *Journal of Wound Care* Published Online:5 Oct 2020
- Gold MH, Andriessen A, Bhatia AC, Bitter P Jr, Chilukuri S, Cohen JL, Robb CW. Topical stabilized hypochlorous acid: The future gold standard for wound care and scar management in dermatologic and plastic surgery procedures. *J Cosmet Dermatol*. 2020 Feb;19(2):270-277.
- Sakarya S, Gunay N, Karakulak M, Ozturk B, Ertugrul B. Hypochlorous acid: an ideal wound care agent with powerful microbicidal, antibiofilm, and wound healing potency. *Wounds* 2014;26(12):342-350.
- Robson MC, Payne WG, et al. Hypochlorous Acid as a Potential Wound Care Agent: Part II. Stabilized Hypochlorous Acid: Its Role in Decreasing Tissue Bacterial Bioburden and Overcoming the Inhibition of Infection on Wound Healing. *J Burns Wounds*. 2007 Apr 11;6:e6.
- Hiebert JM, Robson MC. The Immediate and Delayed Post-Debridement Effects on Tissue Bacterial Wound Counts of Hypochlorous Acid Versus Saline Irrigation in Chronic Wounds. *Eplasty*. 2016;16: e32. Published 2016 Dec 1.
- Niezgodza J, Sordi P, Hermans M. Evaluation of Vashe wound therapy in the clinical management of patients with chronic wounds. *Adv Skin Wound Care* 2010;23(8):352-357
- Oropallo AR, Andersen C et al. Guidelines for Point-of-Care Fluorescence Imaging for Detection of Wound Bacterial Burden Based on Delphi Consensus. *Diagnostics (Basel)*. 2021 Jul 6;11(7):1219

**Vashe® Wound Solution, Urgo Medical North America

** MolecuLight®.