

Introduction

Open fractures are associated with tissue loss and severe injuries to surrounding structures. As such, open fractures are often associated with wound healing complications due to difficulties in obtaining wound closure, infection, and necrosis of soft tissue. Full-thickness acute wounds treated with fish skin grafts heal have been found to heal significantly faster than wounds treated with dehydrated human amnio-chorionic membrane¹. Acellular fish skin grafts contain omega-3 polyunsaturated fatty acids, which reduce inflammatory responses and advance cytokines to promote wound healing²; a new form of these grafts is divided into tiny fragments (0.15 cm) that can mold into wound beds.

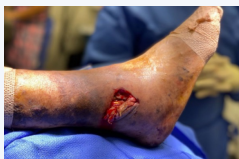

Figure 1: Pre-operative image with exposed peroneal tendons and tissue loss

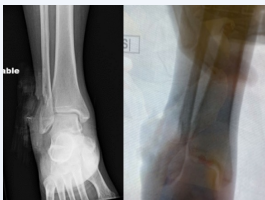


Figure 2: Pre-operative image with exposed peroneal tendons and tissue loss

Methodology & Procedures

Patient presented to the emergency department via EMS, immediately received intravenous first generation cephalosporin antibiotics, and throughout hospital stay. (Figure 1, Figure 2A, 2B) Patient was taken to the OR for washout and primary fracture fixation. Intraoperatively, the wound was explored and appeared to be clean in nature. (Figure 3.) Pulse lavage was then utilized to fully flush out the wound. A betadine and saline mixture were utilized to gently irrigate the wound. Next the distal fibular fracture was evaluated, and there was obvious comminution and defect of the distal fibula. Fracture was reduced with multiple K wires.

Next a pre-contoured distal fibular plate was applied and temporally fixated to bone. (Figure 4) Approximately 3 cc of demineralized bone matrix was mixed with acellular fish skin graft and applied into bony void. (Figure 5) Views were taken and saved illustrating appropriate placement of hardware and a combination of locking and nonlocking screws were placed above below the fracture site.

X-rays taken and saved illustrating appropriate reduction of underlying deformity. Lateral pull test was performed under fluoroscopy illustrating no obvious syndesmotic widening. Wound was fully flush out again with copious amounts of normal saline. The wound appeared to be clean and therefore was loosely closed. Multiple retention sutures were applied to the lateral aspect of the wound.

Disclosures

None

Methodology & Procedures (Continued)

Next vessel loop assisted closure was performed with staple gun and vessel loops due to soft tissue deficit and trauma to underlying deep tissue. (Figure 6) Patient placed in well-padded dressing and posterior mold. Patient remained completely non-weightbearing right lower extremity.

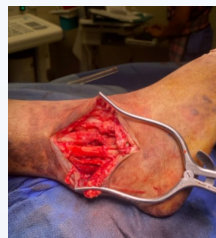

Figure 3: Intra-operative visualization of open fracture site wound was noted to track deep to ankle joint with soft tissue defects but intact peroneal tendons noted.

Results

A strict post-operative protocol of 4 weeks non-weightbearing was instructed to the patient. Patient was evaluated in the clinic week 1 after surgery for incision check, and a splint was re-applied. Week 2 the patient was re-evaluated where sutures and vessel loops were removed successfully. Patient transitioned to weight-bearing as tolerated at week 4. No complications with wound healing were noted.

Discussion

Kerecis® Omega-3 Wound Graft (Kerecis), a new technology incorporating intact fish skin, is rich in omega-3 polyunsaturated fatty acids. Developed in 2009, the graft consists of skin from Icelandic cod. When one applies this modality to wound beds, the graft recruits the body's own cells and is ultimately turned into living tissue. The product itself acts as a bacterial barrier and promotes three-dimensional cellular ingrowth in comparison to human amnion grafts.¹

In a double-blind, randomized trial, Kirsner and coworkers compared the fish skin graft and a dehydrated human amnion chorion membrane allograft for the treatment of acute full-thickness wounds.⁴ In this study involving 170 wounds (85 punch biopsy wounds in each treatment group), the study authors found faster healing with the fish skin graft. Kerecis Omega3 Wound fish skin graft displays rapid incorporation, the ability to granulate over deep structures including bone and tendon, and provides a robust scaffold when tissue deficit coverage is necessary. This novel fish skin graft shows promising results thus far with no adverse events noted.

Further double-blinded, randomized controlled trials are recommended to determine the clinical effectiveness and utility of the Kerecis Omega3 Wound graft for wound healing in the setting of open fractures.

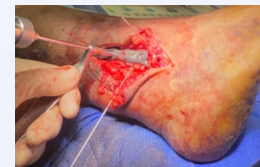

Figure 4: Application of contoured distal fibular plate with temporary k-wire fixation

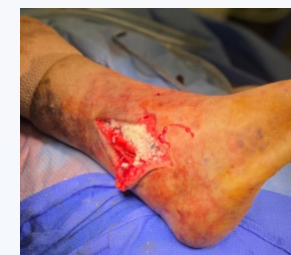

Figure 5: Mixed demineralized bone matrix and acellular fish skin graft packed into bony void and surrounding fibular plate.

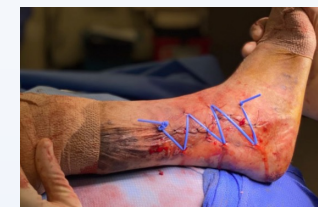

Figure 6: Vessel loop was utilized to assist with closure due to soft tissue deficit and trauma to underlying structures.

References

- Balderson BT, Kjartansson H, Konradsson F, Gudnason P, Sigurjonsson GF, Lund SH. Healing rate and antimicrobial safety of full-thickness wounds treated with fish skin acellular dermal matrix versus porcine small intestine submucosa: a noninferiority study. *Int J Low Extrem Wounds*. 2015;14(1):37-43.
- Cline WW, Swaniolkowski ME. Treatment principles in the management of open fractures. *Indian J Orthop*. 2008 Oct-Dec; 42(4): 377-386.
- Dorweiler B, Tinnh TT, Damchode F, Vahl CF, Debus ES, Storck M, Diener H. The marine Omega3 wound matrix for treatment of complicated wounds. *Gefaschirurgie*. 2018; 23 (Suppl 2): 45-55.
- Kirsner RS, Mangolis DJ, Balderson BT, Petrusdottir K, Davidson OB, Weir D, Luntz JC. Fish skin grafts compared to human amnion-chorion membrane allografts: A double-blind prospective, randomized clinical trial of acute wound healing. *Wound Repair Regen*. 2020 Jan-Feb; 28 (1): 75-80.
- Sethi N, E. I. L. D. J. V. A. Chopra, and Hadar Lev-Tov. "Fish skin grafts with omega-3 for treatment of chronic wounds: exploring the role of omega-3 fatty acids in wound healing and a review of clinical healing outcomes." *Surg Technol Int* 40 (2022): 38-46.