

# Documenting Healing of Diabetic Foot Ulcers Using Mobile Multispectral Near-Infrared Imaging: A Case Series

**Stephanie Woelfel\*, PT, DPT, CWS**

\*Director of Clinical Physical Therapy and Associate Professor of Clinical Physical Therapy & Surgery at USC Division of Biokinesiology & Physical Therapy, Los Angeles, CA

**Objective:** To investigate the utility of mobile multispectral NIRS in objectively documenting the healing of diabetic foot ulcers

## Introduction

Diabetic foot ulcers (DFUs) are a common and debilitating complication of diabetes, often leading to significant morbidity and increased healthcare costs. Accurate assessment of ulcer healing progress is essential for optimizing treatment strategies and improving patient outcomes. Mobile multispectral near-infrared spectroscopy (NIRS) imaging has emerged as a promising non-invasive tool for documenting the healing of DFUs by evaluating tissue oxygenation levels. This case series aims to investigate the utility of mobile multispectral NIRS in objectively documenting the healing process of diabetic foot ulcers.

## Methods

Subjects with DFUs were enrolled into an IRB-approved observational study between March 2023 and August 2023. For this abstract, a case series design was employed that includes subjects with an existing diabetic foot wound. A hand-held multispectral NIRS imaging device\*\* that utilizes near-infrared light to assess tissue oxygenation levels at multiple wavelengths was used. This device also measured skin surface temperature. Patient demographics, clinical characteristics, NIRS measurements, wound characteristics (WIFI classification), and healing outcomes were collected and analyzed.

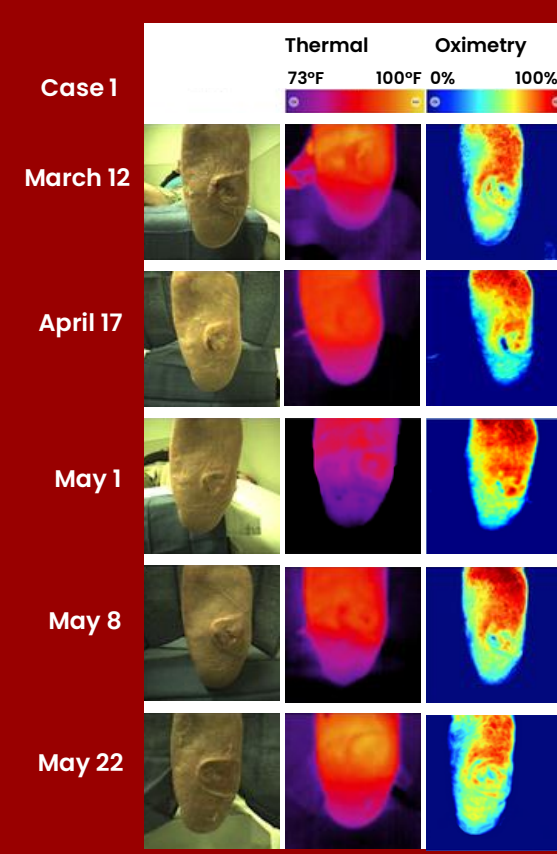


\*\*MIMOSA Pro; MIMOSA Diagnostics, Inc., Toronto, ON.

## Discussion

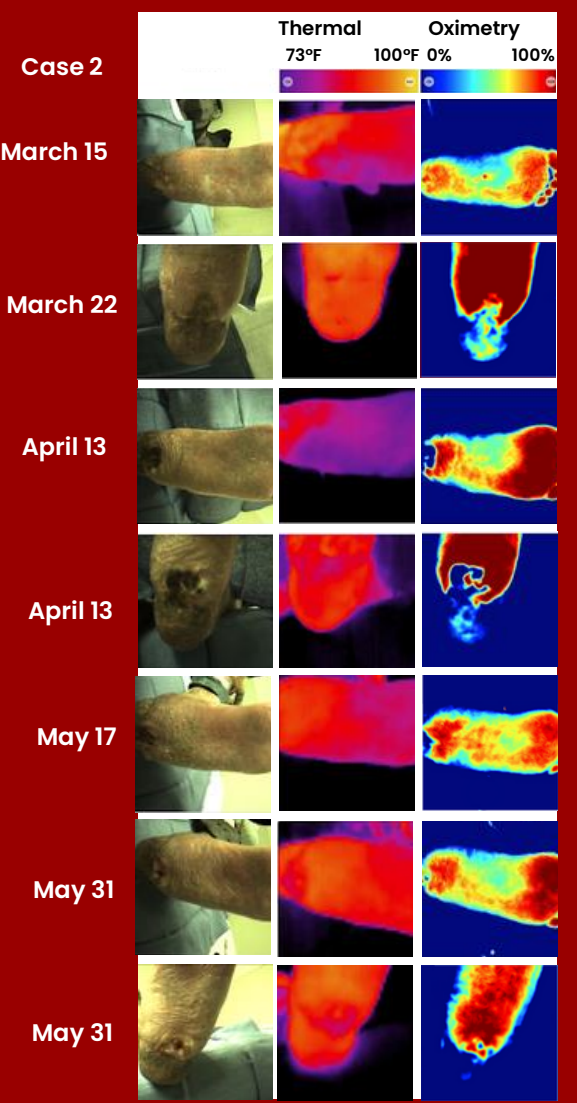
The findings from this case series emphasize the potential of mobile multispectral NIRS imaging as a valuable tool for documenting the healing of DFUs. By providing real-time and objective information on tissue oxygenation, NIRS enables clinicians to track the progress of ulcer healing and evaluate the effectiveness of treatment interventions, which also increased patient engagement and treatment compliance. This information can guide treatment decisions, aid in determining the optimal timing for interventions such as debridement and facilitate targeted wound care strategies. Additionally, the portability and ease of use of mobile NIRS imaging devices make them suitable for regular monitoring in outpatient settings, allowing for timely adjustments to treatment plans based on objective healing documentation.

**RESULTS** The case series consisted of three patients with DFUs of varying sizes and durations. The results demonstrated that healing DFUs exhibited a progressive improvement in tissue oxygenation. NIRS data also provided objective documentation of the temporal healing patterns, allowing for quantitative assessment of the ulcer healing process. Patients were also very interested in the real-time measurements of tissue oxygenation and temperature which increased compliance to therapy and engagement.



**Case 1** – A 54-year-old male with a DFU on the left plantar foot. Medical history includes Charcot deformity and atherosclerosis. He is a non-smoker. Past surgical history includes skin graft to foot in June 2021. At baseline on March 13th, the wound measured 1.5 x 0.5 cm and was profiled as W:1, I:0, Fi:0 as per WIFI classification. Treatment was a custom felted foam orthotic inside of total contact cast throughout the duration of study. On April 17th, a new friction blister was identified due to increased activity from April 3rd to April 16th. The wound re-closed on May 1st, but a new area opened on May 8th. On May 22nd, the participant's wound measured 2.5 x 2.4 x 0.3 cm and was profiled as W:1, I:0, Fi:0. Increases in tissue oxygenation was observed over time within and around the wound when compared to baseline.

**Case 2**– A 45-year-old male with a DFU on the left plantar heel. Medical history includes end-stage renal disease, diabetic neuropathy, kidney transplant in March 2021, hypertension, retinopathy, and past osteomyelitis after multiple distal amputations. He is a non-smoker. His Hgb A1C is 8.3. He had a wound excision and closure of left heel with superficial circumflex iliac artery perforator flap in January 2020. At baseline on March 15, the wound measured 0.7 x 0.4 x 0.2 cm and was profiled as W:1, I:0, Fi: 0. Treatment started with custom felted foam orthotic and football dressing (March 15-April 13), and transitioned to a custom felted foam orthotic in total contact cast until May 24th, where he went back to original treatment. On May 31st, the wound measured 1.3 x 1.3 x 0.8 cm and was profiled as W:3, I:0, Fi:0. Tissue oxygenation increased after baseline in the forefoot, and remained relatively consistent over time. Tissue oxygenation in the heel and wound remained low throughout the study correlating with the wound's chronic nature.



**Case 3** – a 60-year-old male with a DFU on the left hallux. Medical history includes Hepatitis B, HIV, hypertension and peripheral vascular disease. He is a non-smoker. His Hgb A1C is 8.0. Surgical history includes partial left hallux amputation. At baseline on March 7th, the wound measured 1.6 x 1.6 x 0.5 cm and was profiled as W:2, I:0, Fi:0. Treatment was a custom felted foam orthotic (double layer) and wedge shoe throughout. Of note, the patient declined a total contact case due to claustrophobia. On June 16th, the wound measured 1.3 x 0.9 x 1.2 cm and was profiled as W:2, I:0, Fi:0. Visit to visit, tissue oxygenation remained consistent as the wound progressed to a healing trajectory.

