

Management of Chronic Radiation Tissue Necrosis Wounds with Continuous Topical Oxygen Therapy Supports Wound Healing in Patients of Advanced Age

Lawrence R. LoDico III, CWS, ATP, COF • Windy Cole, DPM, CWSP





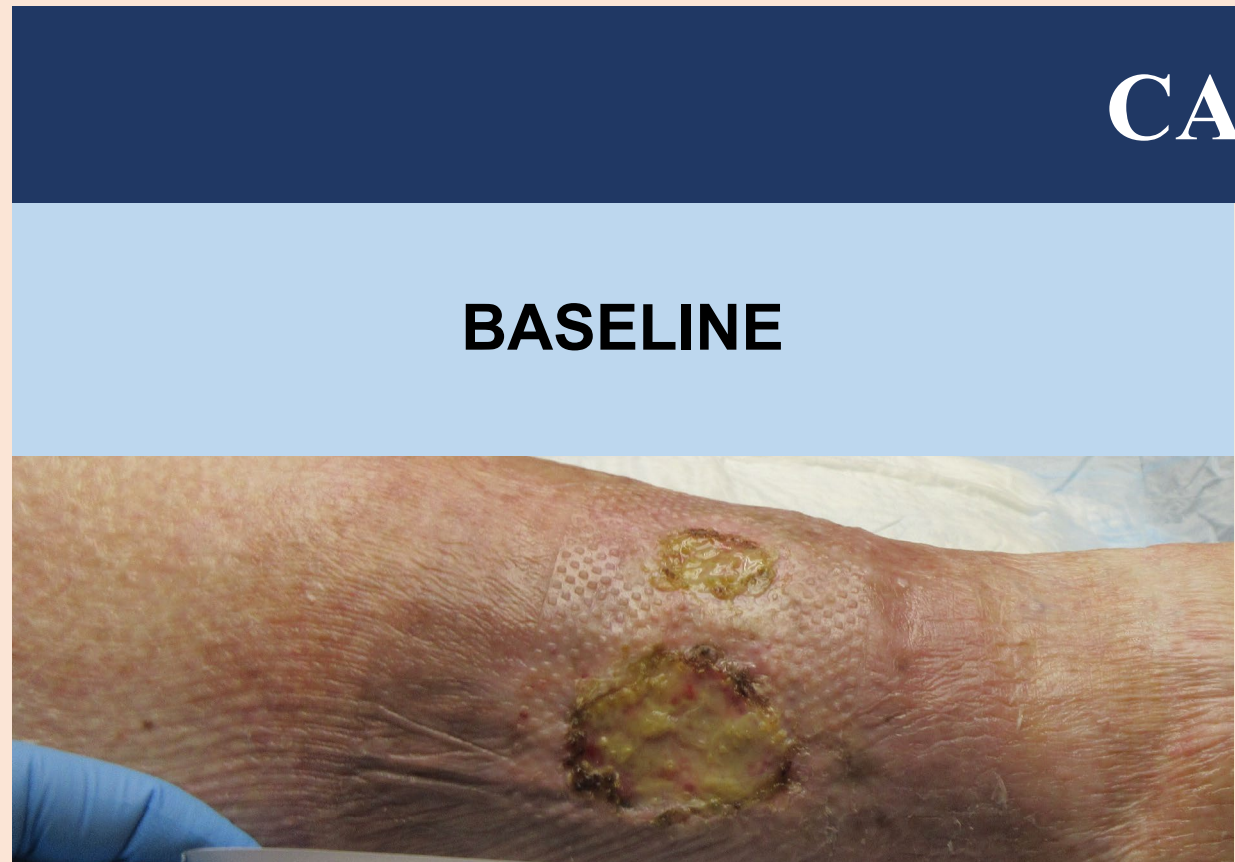

INTRODUCTION

- Radiation therapy is commonly used in the treatment of various skin cancers alone, or in combination with, wide surgical excision or Mohs surgery.
- Radiation therapy can be damaging to the surrounding healthy tissue and often results in tissue necrosis compromising wound healing thus leading to a chronic ulceration.
- As we age, dermal collagen integrity decreases and skin frailty and fragility become more than just a cosmetic concern.
- The term “dermatoporosis” has been coined in the literature to refer to the loss of protective mechanical function seen in aging skin.
- Clinical manifestations of dermatoporosis begin to occur with increased incidence starting as early as age 60 but are more acutely problematic in patients aged 70-90.
- The combination of dermatoporosis, surgical intervention and radiation therapy in elderly patients can lead to serious sequelae such as non-healing, chronic wounds.
- This case series describes the management of chronic radiation wounds post Mohs surgery in three patients of advanced age and with multiple comorbidities using continuous topical oxygen therapy (cTOT).*

METHODS

- Three female participants ages 84, 90 and 93 presenting with a history of non-healing lower extremity wounds due to radiation tissue necrosis were included in this series.
- The median wound duration was 12 months.
- All patients have tried and failed multiple wound care therapies.
- Due to the existence of skin frailty present in this patient cohort along with extensive inflammation and fibrosis of the wound, these patients were not candidates for surgical closure, therefore conservative therapy with cTOT was initiated.
- Patients were seen weekly.
- Wound measurements and images were obtained and recorded.

NATROX[®]
Wound Care

CASE 1	
BASELINE 	COMPLETE EPITHELIALIZATION 5 WEEKS 
<ul style="list-style-type: none">• 85-year-old female presents with a non-healing ulcer of the left lower leg s/p squamous cell carcinoma and radiation therapy• PMH includes coronary artery disease, hyperthyroidism, cardiomyopathy, hyperlipidemia, venous insufficiency and lymphedema• Previous treatments include surgical and ultrasonic debridement, various CAMPs, and compression bandaging• Wound appearance at baseline - friable tissue base with moderate slough• Wound measurement at baseline - 2.5cm x 2.0cm x 0.6 cm• Pain at baseline: 5/10 Pain after cTOT: 0/10• Complete epithelialization was achieved 5 weeks after cTOT was initiated	
CASE 2	
BASELINE 	COMPLETE EPITHELIALIZATION 3 WEEKS 
<ul style="list-style-type: none">• 93-year-old female presents with a non-healing ulcer of the right lower leg s/p basal cell carcinoma and radiation therapy• PMH includes hypothyroidism, peripheral arterial disease, cardiomyopathy• Previous treatments include angioplasty, oral antibiotics, ultrasonic debridement, various CAMPs• Wound appearance at baseline - adherent slough tissue base• Wound measurement at baseline - 3.4cm x 2.2 cm x 0.5cm• Pain at baseline: 10/10 Pain after cTOT: 3/10• Complete epithelialization was achieved 3 weeks after cTOT was initiated	
CASE 3	
BASELINE 	COMPLETE EPITHELIALIZATION 3 WEEKS 
<ul style="list-style-type: none">• 91-year-old female presents with a non-healing ulcer of the right lower leg s/p squamous cell carcinoma and radiation therapy• PMH includes cardiomyopathy, cellulitis of lower extremity, lymphedema, hypertension, hyperlipidemia, obesity, and hypothyroidism• Previous treatments include ultrasonic debridement, various CAMPs, and compression bandaging• Wound appearance at baseline - slough covered• Wound measurement at baseline - 3.0cm x 2.5cm x 0.6cm• Pain at baseline: 5/10 Pain after cTOT: 0/10• Complete epithelialization was achieved 3 weeks after cTOT was initiated	

*NATROX[®] Wound Care is a brand of Inotec AMD Ltd. NATROX[®] O₂ is a registered trademark of Inotec AMD Ltd.

RESULTS

- Having failed multiple other advanced wound care treatment modalities these three patients received conservative management using cTOT.
- This treatment algorithm resulted in positive healing trajectories in all three patients.
- Additionally, all patients relayed a decrease in wound pain with the use of cTOT.
- Leveraging cTOT in an outpatient setting resulted in complete closure of these refractory radiation wounds with an average time to complete epithelialization of 3.6 weeks.

DISCUSSION

- Standardized treatment for chronic radiation-induced wounds, especially in the elderly population is lacking.
- Conservative wound care consisting of cleaning, debridement, infection control, and nutritional support often fail to support wound healing.
- The benefits of cTOT for the management of chronic wounds has been extensively outlined in the literature.
- Given the mechanism of action of cTOT, the authors believe that re-establishment of adequate blood and oxygen to wounded tissues supported rapid wound healing and pain relief. Positive outcomes exhibited in this case series suggest that cTOT is an effective treatment in the management of patients with compromised wound healing due to radiation, advanced age, and comorbidities.

REFERENCES

- Kaya G, Saurat JH. Dermatoporosis: a chronic cutaneous insufficiency/fragility syndrome. Clinicopathological features, mechanisms, prevention and potential treatments. *Dermatology*. 2007; 215(4): 284-294.
- Kimmel, H. M., Grant, A. & Ditta, J. (2016) The presence of oxygen in wound healing. *Wounds* 28(8), 264-270.
- Natura, T. D., van Hinsbergh, V. W. M., Koolwijk, P. (2014) Hypoxic signaling during tissue repair and regenerative medicine. *International Journal of Molecular Science*, 15(11), 19791-19815.
- Cullen, B., Elisa, A. A. A., Kauffman, et al. (2018) Consensus round table meeting: Topical oxygen therapy for healing complex wounds. London: *Wounds International*, 1-20.
- Tang, T. Y., Chong, T. T., Wang, J. CC., et al. (2018) Natrox - Let the topical oxygen flow for healing complex wounds. *Wounds Asia*, 1(2).
- Younis I. (2020) Role of oxygen in wound healing. *Journal of Wound Care*, 29(Sup5b), S4-S10.

FOR MORE INFORMATION

Lawrence R. LoDico III, CWS, ATP, COF
• Wound Care Clinic of South Jersey
LoDico45@me.com

Windy Cole, DPM, CWSP
• Director, Wound Care Research
Kent State University College of Podiatric Medicine
• Global Medical Affairs Director
NATROX Wound Care
Windy.Cole@Natroxwoundcare.com