

Novel use of a nylon hooked medical fabric for compassionate debridement and wound bed preparation prior to grafting



Laura Swoboda DNP, APNP, FNP-C, FNP-BC, CWOCN-AP, WOCNF; *the Healing Institute, Metro Milwaukee, Wisconsin*

Background/Introduction: Debridement of complex wounds is a standard of care, and should be utilized as part of a proactive protocol of care at each patient encounter. Nylon hooked medical fabric is a frictional method of debridement with enhanced versatility through its application to a variety of surfaces.

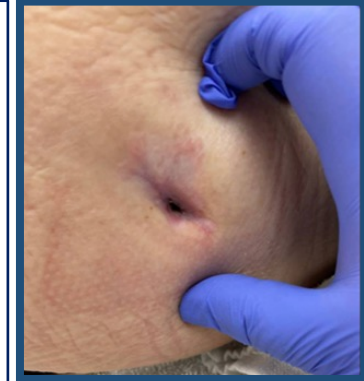Methods: Wound bed preparation was initiated including soap and water cleansing and administration of hypochlorous acid. Non-viable and hyper-granular tissue was then debrided to the level of viability using frictional hook/curette fabric to create a level wound bed for centripetal epithelial edge migration. Advanced wound care dressings or cellular tissue products were then applied to expedite wound healing.

Results:

Case 1: A 67 year old female developed a non-healing left buttock pressure injury due to immobility and positioning related to multiple sclerosis. At initiation of frictional fabric-based debridement the wound had epithelialized minus a 5cm tunnel stalled for greater than 1 year. The debridement procedure was well tolerated in this sensate wound; no non-verbal signs/symptoms of pain noted.

Case 2: A 64 year old male with a stalled diabetic foot ulcer underwent preparation for cellular tissue product application. Following debridement wound bed preparation for the living cellular allograft application was further facilitated using a gentle tapping technique to create micro-punctate incisions throughout the wound bed to further stimulate healing and promote graft activity.

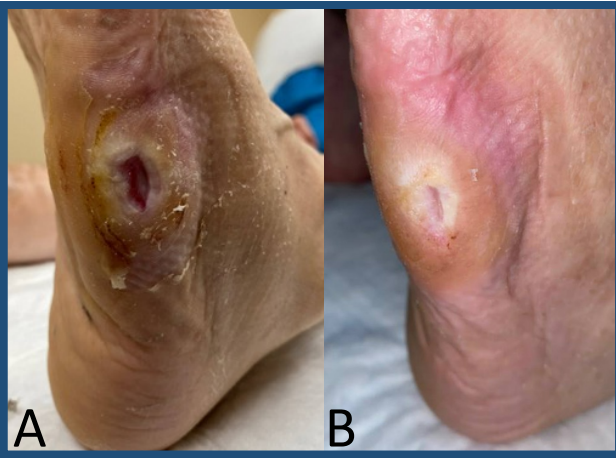Case 3: An 80 year old female with diabetes, protein-calorie malnutrition, and chronic pain was seen for a sacro-coccygeal pressure injury. Frictional debridement effectively removed hypergranulation tissue throughout to establish a flush wound edge. The wand shape applicator was utilized to provide compassionate debridement of a stalled 3cm tunnel. No non-verbal signs/symptoms of pain noted during debridement. At the 4 week follow up wound dimensions in centimeters squared had decreased 17% with complete resolution of the 3cm tunnel. At 6 week follow up the wound was completely epithelialized and the patient was able to resume baseline activities of daily living.



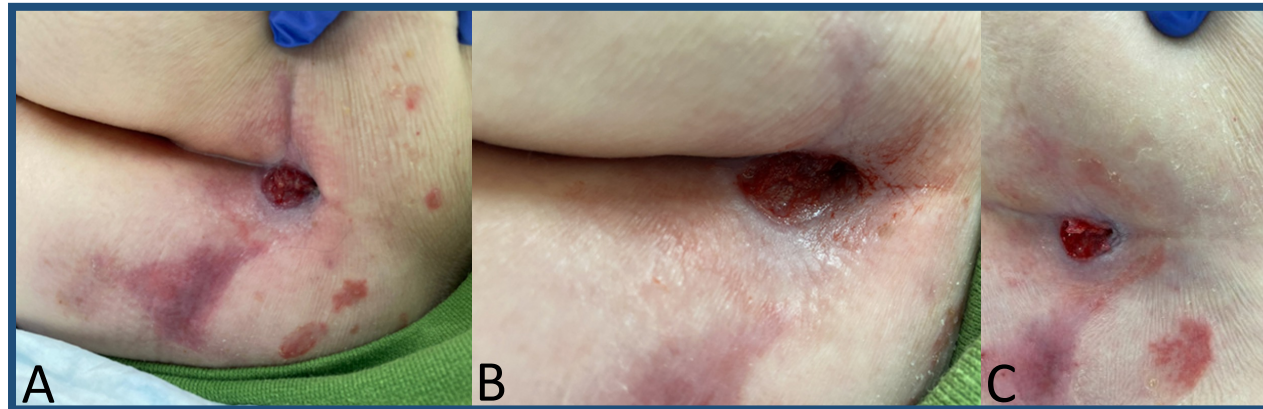
Case 1: Left buttock wound small os, stalled, prior to nylon hooked medical fabric

Discussion: Nylon medical fabric is coated in plastic hooks that become micro-curettes with pressure and can remove varying levels of tissue dependent on technique. Initially developed to create an option with increased tolerance during endo-cervical biopsy, the technology was noted to be able to debride tissue in wounds with the similar qualities of efficacy. The hooked fabric debridement tool can also be utilized to collect specimens for molecular DNA analysis, culture, and anatomic pathology analysis.

References:
Borg, et al. Trans Epithelial Endocervical and Exocervical Biopsy with Minimally Invasive Fabric Based Devices. J. Lower Gen Tract Dis/col. Sixteen, Number Two, April 2012 Supplement pg. 522
Winter, et al. Fabric-Based Exocervical and Endocervical Biopsy in Comparison with Punch Biopsy and Sharp Curettage. J. Lower Gen Tract Dis., Vol. Sixteen, Number Two, April 2012 pg. 40-47
Diedrich et al. Improvement in Endocervical Yield with Fabric Curettage. J. Lower Gen Tract Dis, April 2014 - Volume 18 - Supplement 1 S, p. 519.
Clark et al. High Correlation of Fabric-based Cervical Biopsy to SubsequentLEEP. J. Lower Gen Tract Dis, April 2014 - Volume 18 - Supplement 1 S, p. 522.
Clark et al. Observation of a Robust Immune Inflammatory Response Following Frictional Fabric Biopsy During Colposcopy. J. Lower Gen Tract Dis, April 2014 - Volume 18 - Supplement 1 S, p. 521.
Yeh et al. Feasibility to Diagnose Cervical Cancer During Colposcopy Using Fabric-Based Minimally Invasive Biopsy Devices. J. Lower Gen Tract Dis, Volume 20, Number 2, Supplement 1, April 2016, p. 522.
Yeh et al. Wound Care: A Comparison of Spiral Biopsy and Fabric-Based Minimally Invasive Exocervical Biopsies Relative to Punch Biopsy. J. Lower Gen Tract Dis, Volume 20, Number 2, Supplement 1, April 2016, p. 523.



Case 2: A) Prior to graft prep with nylon hooked medical fabric B) 5 weeks post graft



Case 3: A) Prior to frictional fabric based debridement; B) post debridement C) 4 week follow up 17% smaller, 3cm of tunneling at 12 o'clock resolved.