

# Dehydrated Human Amnion Chorion Membrane (DHACM) Use in Patients with Emergent Craniectomies Demonstrates Minimal Dural Adhesions at Time of Cranioplasty

Jeff Ehresman, MD<sup>1</sup>; ENS Luke Endicott, MC, USNR<sup>2</sup>; William Tettelbach<sup>3,4,5,6,7,9</sup>; Allyn Forsyth<sup>7,8</sup>; Bryan Lee, MD<sup>1</sup>

## INTRODUCTION

The incidence of subdural hematomas (SDH) in patients with a significant head injury has been projected to be between 5% to 25%. There is an estimated annual incidence of one to five cases per 100,000 population annually with a male to female ratio of 2:1.[1] Although practiced since the beginning of the 20<sup>th</sup> century [2], decompressive craniectomies (DCs) are still commonly complicated with epidural fibrosis post cranial resection, resulting in adherence of the dura to both the brain internally and skin flap externally. This becomes especially problematic in the setting of skull flap replacement as adhesions can lead to a bridging vein tear in addition to other postoperative complications. Dural adjuvants which can potentially contribute to decreased rate of adherence formation can by this means favorably impact both postoperative cranioplasty complications and operative duration. DHACM has been shown to reduce the rate of dural scar tissue formation in re-exploration of posterior lumbar interbody fusions operations which required entry into the epidural space.[3] Current literature suggests earlier repairs (<7 weeks) to be associated with higher rates of post-operative infection and hydrocephalus while delayed repair (>3 months) are associated with higher rate of seizures and permanent neurological deficits.[4] The purpose of this pilot study was to evaluate whether DHACM used in the setting of emergent craniectomies decreased rate of dural adhesion formation and subsequent cranioplasty complications.

## METHODS

Patients were retrospectively screened based on having undergone emergent DC for a traumatic brain injury (TBI) or malignant edema secondary to a cerebral infarction of the middle cerebral artery (MCA) where either group received DHACM anti-adhesion protocol. Obligatory secondary cranioplasties (CPs) were performed and only patients who survived extensive efforts to follow-up cranioplasty were included in the overall patient population as to allow for review of fibrotic changes within the dural space. Seven patients were found which met criteria and were included in the primary outcome measurements. The primary objective was to qualitatively evaluate adhesion formation in patients who received intraoperative DHACM interlay/overlay during emergent DC (figure 1). Secondary outcomes include estimated blood loss during CP, time dedicated to dissection/exposure, and post-surgical complications. The study was reviewed and approved by the site's institutional IRB.

## References

1. Tenny S, Thorell W. Intracranial Hemorrhage. [Updated 2023 Feb 13]. In: StatPearls [Internet]. Treasure Island (FL): StatPearls Publishing; 2023 Jan-. Available from: <https://www.ncbi.nlm.nih.gov/books/NBK470242/>
2. Kocher T. Die therapie des hirndruckes Hirnerschütterung. *Hirndruck und chirurgische Eingriffe bei Hirnkrankheiten*. 1901;3:262-6.
3. Subach BR, Copay AG. The use of a dehydrated amnion/chorion membrane allograft in patients who subsequently undergo reexploration after posterior lumbar instrumentation. *Adv Orthop*. 2015;2015:501202. doi:10.1155/2015/501202
4. Smith M. Refractory Intracranial Hypertension: The Role of Decompressive Craniectomy. *Anesth Analg*. 2017;125(6):1999-2008. doi:10.1213/ANE.0000000000002399

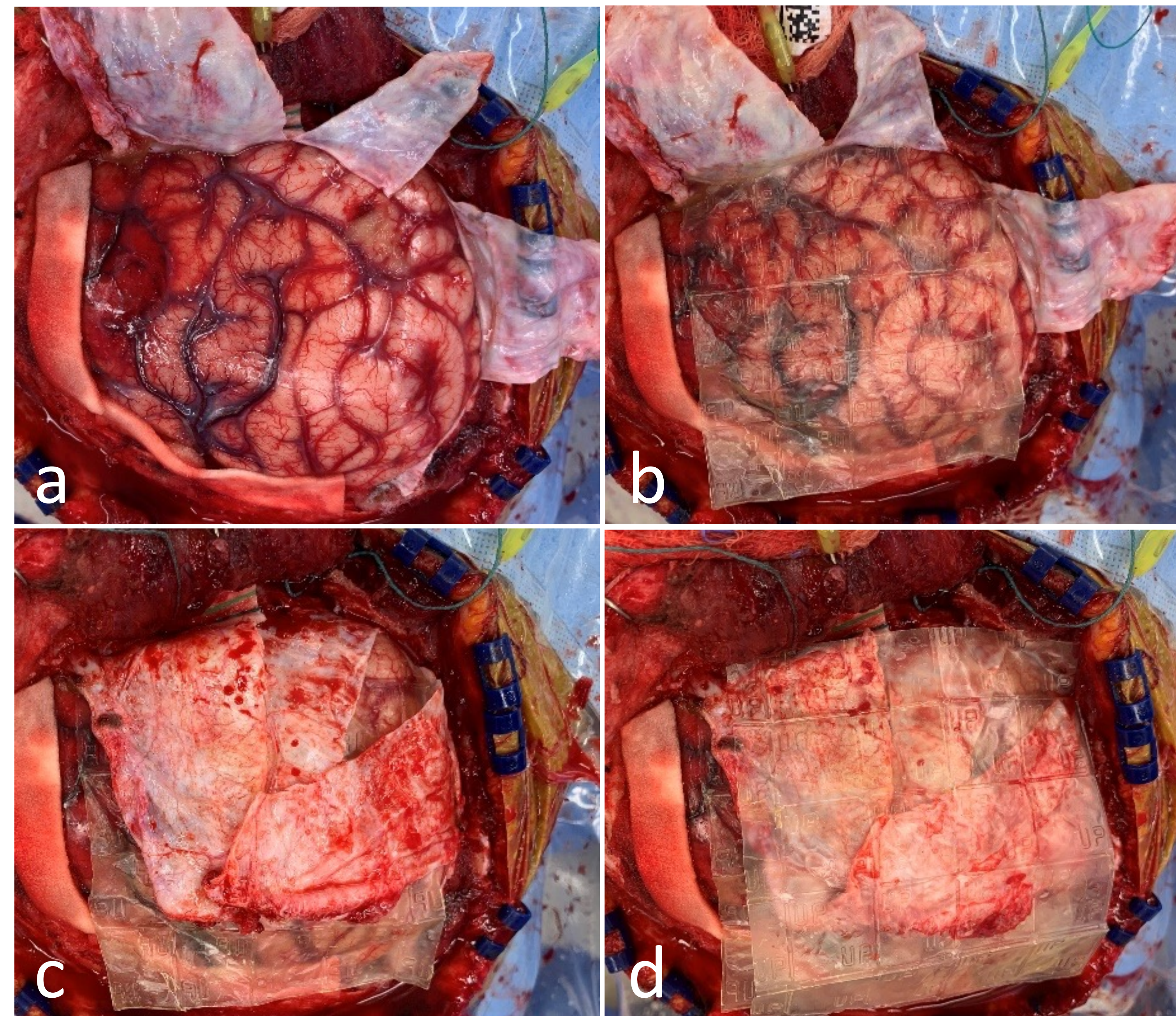


Figure 1. Steps a-d of inserting DHACM as inlay and overlay during craniectomy closure

## RESULTS

Of the seven patients, five (71%) had undergone emergent decompression due to SDH secondary to traumatic injury while the additional two patients (29%) had right MCA infarctions resulting in malignant edema and large midline shift. The average age of patients was 43 years (+/- 8.6 CI: 95%) with a range of 28 to 63 years old. Five of the seven patients were male (71%). The mean CP procedure time was 79.2 minutes. Time to replacement of autologous bone flap or implant ranged from 36 to 176 days (1-5 months) across the seven patients. When looking at mechanism of injury, those categorized as traumatic SDH had 99.4 days delay prior to CP while those with right MCA infarcts waited on average 140.5 days prior to CP. Table 1 outlines patient demographics, locations and mechanism of injury, blood loss and overall time from primary DC to CP in days. Qualitative assessment of the degree of adhesions at time of cranioplasty revealed minimal restrictions or increased effort required secondary to dural fibrosis. 86% (6/7) of patients demonstrated no adhesions at the time of the obligatory secondary CP. One (14%) of the seven patients was found

\*DHACM = AMNIOFIX (MIMEDX Group, Inc, Marietta, GA, US)

Poster development supported by MiMedx Group, Inc., Marietta, GA,

## RESULTS

Table 1. Demographics, locations, mechanism of injury, blood loss and time between DC to CP

Patient	Age	Gender	Laterality	Mechanism	EBL	CP duration (minutes)	DC to CP (days)
1	36	M	Right T	SDH	50mls	86	36
2	28	M	Right FTP	SDH	50mls	100	176
3	31	F	Right T	SDH	50mls	69	105
4	54	M	Left F	SDH	50mls	64	103
5	46	M	Right FT	MCA Infarct	50mls	84	131
6	63	M	Left T*	SDH w/ partial lobectomy	100mls	68	77
7	43	F	Right FT	MCA Infarct	100mls	84	150
Average	43	-	-	-	64.2mls	79.2 minutes	111 days

T: temporal, F: frontal, FT: frontotemporal, FTP: frontotemporal parietal, T\*: temporal with partial lobectomy, EBL: estimated blood loss

to have significant adhesions formed, yet perioperative notes did not show evidence of complications in dissection in this patient. Due to the small patient population, it cannot be determined the relationship between fibrosis of the dura mater and time delay between repairs. Secondary metrics including time dedicated to dissection, estimated blood loss (EBL), and post-surgical complication were assessed using all hospital, clinic, or telehealth reports made at time of cranioplasty or during follow-up. Estimated time spent dissecting and exposing skull defect during the CP prior to implantations was under 3 minutes per operative report and neurosurgeon self-assessment. Estimated blood loss was minimal ranging from 50-100 mLs with an average of 64.2 mLs. Post-operative repair complications were minimal in the immediate interval; however, one patient did require redo-cranioplasty secondary to acute fluid collection inducing midline shift after initial repair. Lastly, of all the patients who had continuous surveillance and follow-up visits, seizures, a known post DC issue, were the most noted complication. However, the secondary outcome analysis, which included post-surgical complications (e.g., seizures) was limited due to insufficient power of the study.

Table 2. T-test between patient with and without seizure comparing time delayed from DC to CP

Group	n	Mean DC to CP (days)	Standard Deviation
Seizure	3	119.33	26.12
No Seizure	3	87.67	26.87
Total	6	103.50	30.68
t-value	-1.357		
p-value	0.233		

## CONCLUSION

DHACM is a biologic tissue which has been safely used in a wide variety of surgical settings. Its potential as a physical barrier which can aid in supporting an intracranial environment that can ameliorate reactive fibrosis in decompressive craniectomy patients is promising. Further research with larger patient volume and controls arms would be invaluable in determining the full therapeutic effect compared to current anti-adhesion protocols.

## Author Affiliations

1. Barrow Neurosurgical Institute, Department of Neurosurgery, Brain & Spine, Phoenix, AZ; 2. Arizona College of Osteopathic Medicine, Glendale, AZ; 3. Duke University School of Medicine, Department of Anesthesiology, Durham, NC; 4. American Professional Wound Care Association, LA; 5. Association for the Advancement of Wound Care, WI; 6. HCA Healthcare, Mountain Division, Salt Lake City, UT; 7. MIMEDX Group, Inc., Marietta, GA; 8. Department of Biology, San Diego State University, San Diego, CA; 9. Western University of Health Sciences, College of Podiatric Medicine, Pomona, CA