

# Utilization of a 3D Electrospun Synthetic Polymer Matrix (3DESPM) on complex Venous Leg Ulcers to stimulate a regenerative response for wound healing

Simon Tabchi, DPM, FACFAS, PACE Foot & Ankle Associates



## Introduction

Non-healing wounds, burns and ulcers affect approximately 8 million Americans annually with a total cost of care to the health system of approximately \$25B[1]. Alarming, chronic non-healing wounds such as, DFUs, VLU, pressure injuries and ulcers of mixed etiology, are responsible for the greatest number of skin disease deaths (~30%) after skin cancer[1,2].

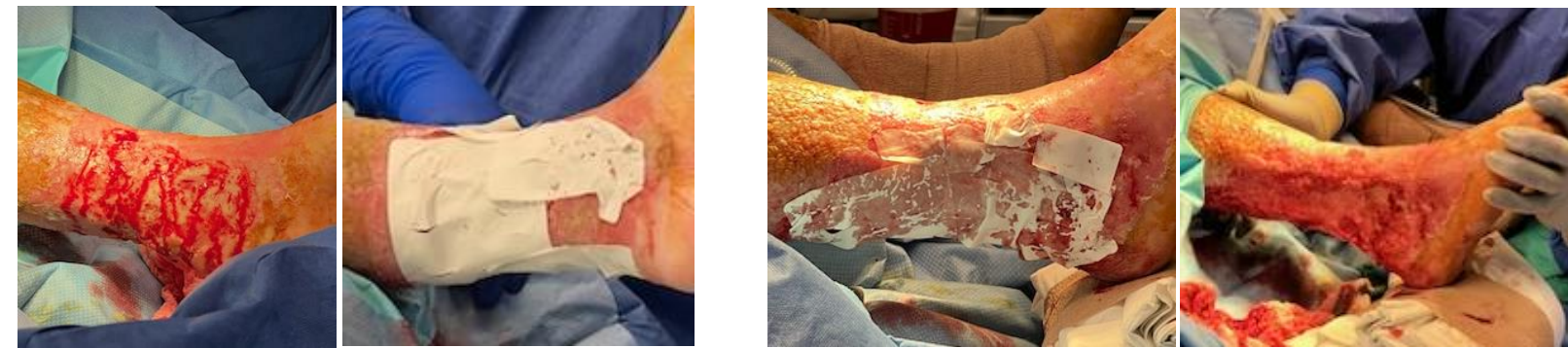Collagen and Extracellular Matrices (ECMs) are commonly used to act as a scaffold for cellular deposition and expansion to repair damaged tissue. Studies have shown electrospun synthetic scaffolds possess the requisite properties known to promote functional tissue regeneration that allows for natural cellular regeneration and skin formation to occur. [3]

## 3D Electrospun Synthetic Polymer Technology (3DESPM)

Scientifically engineered to mimic native extracellular matrix (ECM) morphology, 3DESPM provides a multi-dimensional solution to wound healing. The resorbable synthetic polymer scaffold facilitates pro-regenerative cellular migration, infiltration, adhesion, and proliferation for the tissue regeneration and repair of acute and chronic wounds, and burns.

Comprised of *poly-glycolic acid* (PGA) and *poly-lactide co-caprolactone* (PLCL) synthetic polymers 3DESPM naturally degrades into  $\alpha$ -hydroxy acids and fatty acids, known by the body to stimulate regenerative wound healing by quickly lowering pH, facilitating lactate mediated effects and oxygen perfusion to restore regenerative wound healing of functional tissue.

## Complex, non-healing Venous Ulcers of lower extremities >1-year in duration



**RLE**  
RLE: 15cm x 26cm x 0.4cm

7/8/2022

**LLE**  
LLE: 16.5cm x 29cm x 0.3cm

OR hydro surgical debridement  
1<sup>st</sup> application of PHOENIX – graft quickly integrates

## Discussion

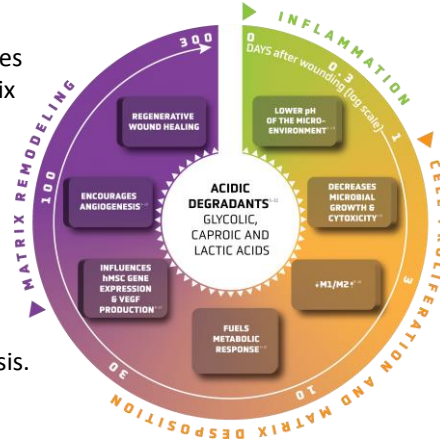
3DESPM demonstrated a unique solution to battling venous disease.

- An acceleration of the stalled wound healing of complex LE wounds was observed
- Reduction in patient pain score after 1<sup>st</sup> application
- RLE achieved PAR of 73% within 3 mos/3 applications
- LLE achieved a PAR of 77% within 3 mos/3 applications
- Restored functional tissue with 3DESPM warrants further research

## Methods

This case series studied the unique properties of a 3D electrospun synthetic polymer matrix (3DESPM) to accelerate the stalled wound healing of complex venous ulcers (VLUs).

3DESPM was selected due to its biomimicry of native ECM, and by design, naturally biodegrades into  $\alpha$ -hydroxy acids and fatty acids known to support low pH and lactate mediated effects, to accelerate regenerative wound healing and angiogenesis. [3-11]



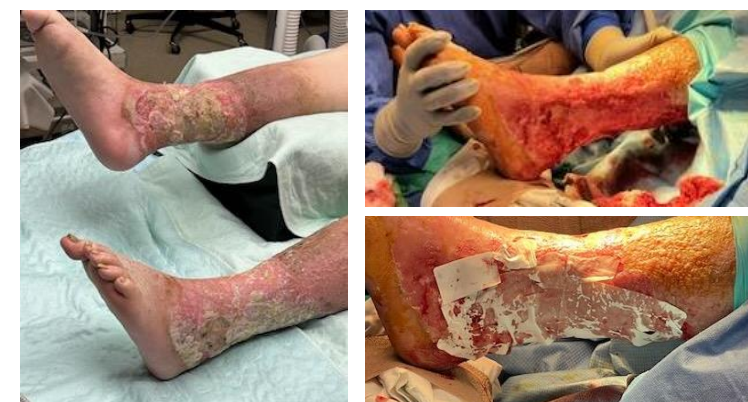## Patient History

History of hypertension, obesity, post laminectomy syndrome, lumbar stenosis, colon cancer and breast cancer screening, malfunction of intrathecal infusion pump, therapeutic opioid-induced constipation (OIC), positive depression screening, chronic pain of left knee and left hip, idiopathic scoliosis, primary osteoarthritis of right hip, chronic pain, lymphedema of both lower extremities, stasis dermatitis ulcerations of both legs >1-year in duration.

Patient became wheelchair bound July 2021 secondary to a fall. Prior Tx was silver alginate, advanced wound care dressings and light compressive wrap. Patient has significant pain to both legs.

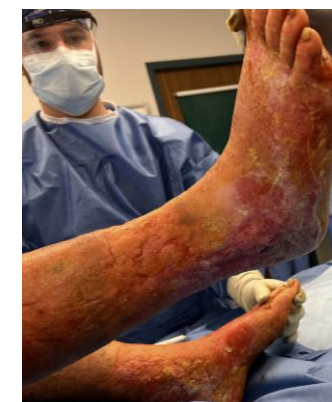## Treatment strategy and outcomes with 3DESPM

- Hydro surgical debridement performed in the OR. 3DESPM was applied, covered with a non-adherent, and bolstered in place under compression.
- After 1 application of 3DESPM, acceleration of the stalled wound healing process was observed. Patient expressed a notable reduction in pain at the wound sites.
- Within 3 months and 3 applications, the right lower extremity achieved a PAR of 73%. The left lower extremity achieved a PAR of 77% in wound size.
- Restored functional native tissue regenerated on these complex, lower extremity non-healing VLUs with 5 applications of 3DESPM.

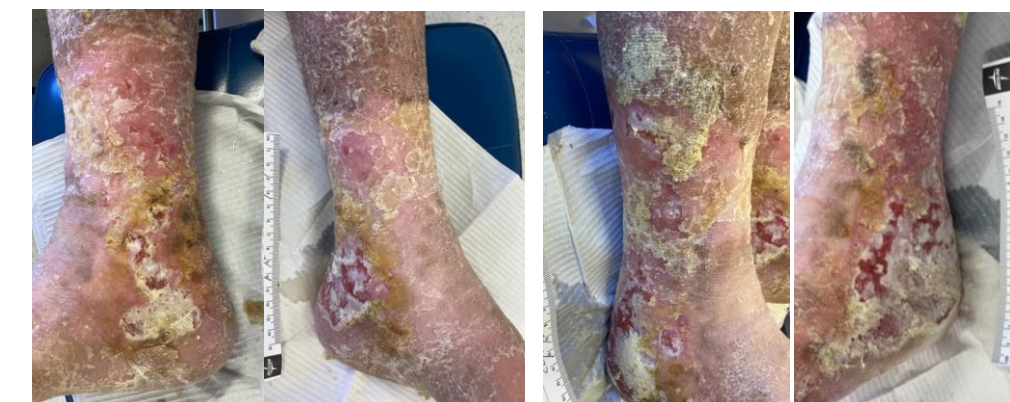

**8/24/2022**  
RLE: 18.8cm x 27.7cm x 0.4cm  
LLE: 21.5cm x 27cm x 0.4cm

Accelerated healing trajectory  
2<sup>nd</sup> Application



**12/14/2022**  
4<sup>th</sup> application



**9/14/23**  
L medial: 5.0cm x 3.2cm x 0.1cm  
R medial: epithelialized  
L lateral: 3.5cm x 3.5cm x 0.1cm  
R lateral: 5.5cm x 2.2cm x 0.1cm