


# Utilization of a 3D Electrospun Synthetic Polymer Matrix (3DESPM) for limb salvage and functional tissue regeneration of complex lower extremity wounds

Simon Tabchi, DPM, FACFAS, PACE Foot & Ankle Associates



**Introduction**  
 In the US 185,000 amputations are performed annually. [1] Among those living with limb loss, the main causes are vascular disease (54%) including diabetes and peripheral arterial disease, trauma (45%) and cancer (< 2%). [2] Nearly 50% who have had an amputation due to vascular disease will die within 5 years [3].

**Methods**  
 This case series evaluates the role of 3D electrospun synthetic polymer matrix (3DESPM) to thwart further amputation and accelerate the wound healing process of complex chronic wounds. 3DESPM was selected due to its biomimicry of native ECM, and by design, naturally degrades into  $\alpha$ -hydroxy acids and fatty acids known to support low pH and lactate mediated effects, to accelerate regenerative wound healing and angiogenesis. [4-8]

Three patients with complex non-healing wounds facing amputation were evaluated.

**Patient Histories and 3DESPM treatment strategies**

**Patient 1**  
 Type 1 diabetes presented with a diabetic foot infection. Assessment: soft tissue abscess at the plantar aspect of the 1st metatarsal. Wound size 10.0cm x 8.0cm x 6.0cm. After surgical resection, 3DESPM was applied.

- Within 7 days a decrease in the inflammatory response and appearance of granular tissue was observed.
- After 2<sup>nd</sup> application an acceleration in the healing trajectory with a PAR >60% in wound size was achieved in 4 weeks.
- Patient transitioned to WCC for continued healing.

**Patient 2**  
 Active patient had an **8-year non-healing wound**, off her foot most of that time. Patient presented to me for a below-knee amputation (BKA) opinion to receive a prosthetic to go back to walking.

- Thorough surgical debridement
  - 3DESPM was applied and the patient was off-loaded
  - Complete closure was achieved within 4 weeks.
- Patient remained healed 1 month after closure and is walking again.

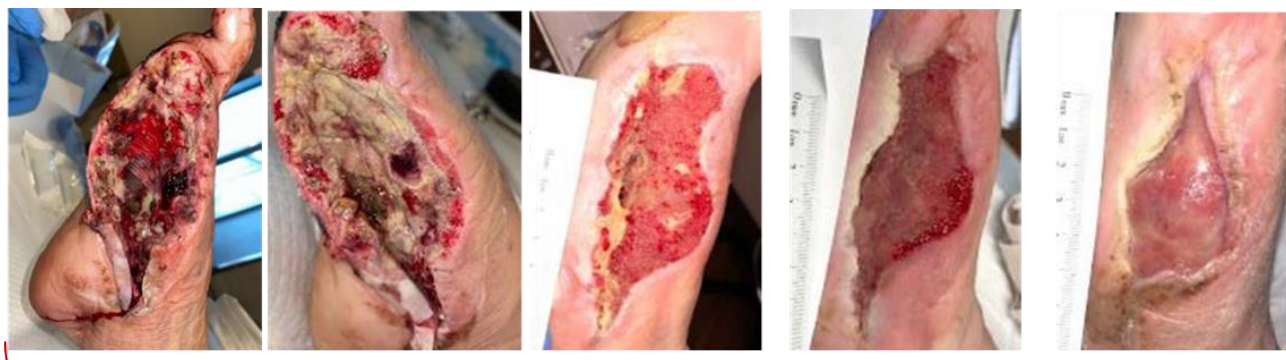**Patient 3**  
 Type 2 diabetes, HbA1c of 10.2, hypertension and neuropathy. Presented with worsening diabetic foot infection. Assessment: Medial skin ulceration 1st toe at level of interphalangeal joint, associated subcutaneous edema indicating cellulitis, no collection to indicate abscess formation. No underlying T1 replacement signal to suggest osteomyelitis. Patient was taken to the OR for I&D.

- Surgical site was completely dehisced and sent back to the OR. Wounds measured 8.0cm x 8.0cm x 2.5cm combined.
- 3DESPM was applied in combination with NPWT. 80% reduction in size achieved within 3 weeks.
  - Complete closure of both wounds within 3.5 months.

**3D Electrospun Synthetic Polymer Technology (3DESPM)**  
 Scientifically engineered to mimic native extracellular matrix (ECM) morphology, 3DESPM provides a multi-dimensional solution to wound healing. The resorbable synthetic polymer scaffold facilitates pro-regenerative cellular migration, infiltration, adhesion, and proliferation for the tissue regeneration and repair of acute and chronic wounds, and burns.  
 Comprised of *poly-glycolic acid* (PGA) and *poly-lactide co-caprolactone* (PLCL) synthetic polymers 3DESPM naturally degrades into  $\alpha$ -hydroxy acids and fatty acids, which stimulate pro-regenerative cellular activity for wound healing. 3DESPM acts as a protective barrier, supporting a pro-healing wound environment, by facilitating low pH and lactate mediated effects known to accelerate regenerative wound healing. 3DESPM demonstrated a reduction in pH from 7.4 to 4.75 within a 1-week period during an in vitro degradation test in isotonic PBS solution (unpublished).

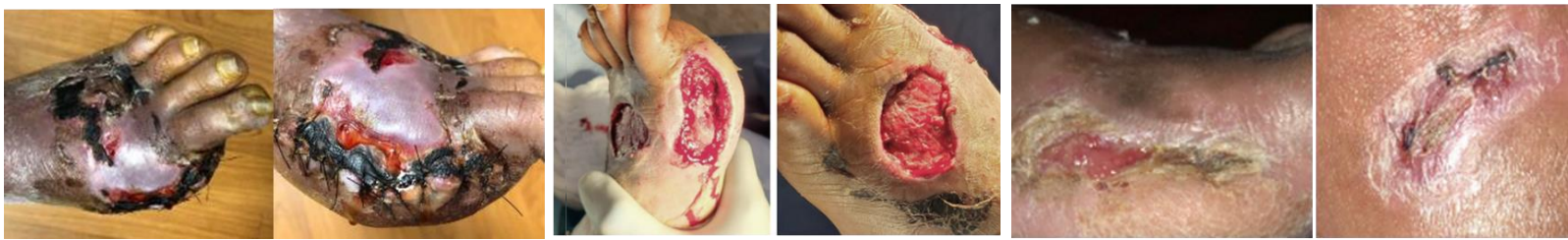**Complex, non-healing lower extremity wounds at risk of amputation**

**Patient 1 – Diabetic foot infection with soft tissue abscess**



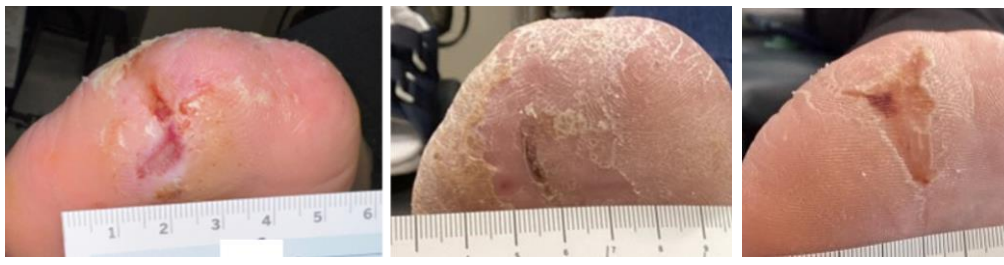
11/17/2021 to 2/9/2022 – 3.5 months progression with 3DESPM				
Wound size: 10.0cm x 8.0cm x 6.0cm	Wound size: 10.0cm x 8.5cm x 6.0cm	Wound size: 9.0cm x 4.5cm x 3.0cm	Wound size: 9.5cm x 3.5cm x 0.6cm	Wound size: 6.2cm x 3.0cm x 0.5cm
1 <sup>st</sup> application	2 <sup>nd</sup> application <b>Granular tissue present</b>	3 <sup>rd</sup> application  Accelerated healing trajectory	<b>Patient transferred to wound center for closure.</b>	

**Patient 3 – Diabetic foot infection with soft tissue abscess**



1/25/2022 to 3/30/2022 – 8 weeks progression with 3DESPM		
1/25/2022 Dehisced surgical site	1/27/2022 Combined wound size: 8.0cmx8.0cmx2.5cm PHOENIX applied in combination with NPWT	3/30/2022 Complete closure of the dorsal wound within 8 weeks
<b>3 applications of 3DESPM</b>		

**Patient 2 – 8-year non-healing wound – BKA consult for prosthetic**



2/23/2023 to 3/22/2023 Complete closure within 4 weeks	10/5/2023 Wound remains closed
1 application of 3DESPM 1 month after closure and patient was walking again	

**Discussion**  
 3DESPM has demonstrated an acceleration in the stalled wound healing of complex lower extremity wounds with a decreased time to closure and preservation of limbs.

- An acceleration of the stalled wound healing of complex LE wounds was observed
- 80% median PAR within 8 weeks
- 2-4 applications to closure (average)
- Regeneration of normal skin tissue, matching ECM
- Reduction in further amputation
- Reduction in wound reoccurrences
- Restored functional tissue with 3DESPM warrants further research



**REFERENCES:** 1. Dillingham TR, Pezzin LE, Shore AD. Reamputation, mortality, and health care costs among persons with dysvascular lower-limb amputations. Arch Phys Med Rehabil. 2005 Mar;86(3):480-6. 2. Beckman JA, Creager MA, Libby P. Diabetes and atherosclerosis: epidemiology, pathophysiology, and management. JAMA. 2002 May 15;287(19):2570-81. 3. Moxey PW, Gogalniceanu P, Hinchliffe RJ, Loftus IM, Jones KJ, Thompson MM, Holt PJ. Lower extremity amputations—a review of global variability in incidence. Diabet Med. 2011 Oct;28(10):1144-53. 4. Bosse MJ, MacKenzie EJ, Kellam JF, Burgess AR, Webb LX, Swionkowski MF, Sanders RW, Jones AL, McAndrew MP, Patterson BM, McCarthy ML, Trivison TG, Castillo RC. An analysis of outcomes of reconstruction or amputation after leg-threatening injuries. N Engl J Med. 2002 Dec 12;347(24):1924-31. 5. Gethin G. The significance of surface pH in chronic wounds. Wounds UK 2007; 3: 52-6. 6. Jones, E.M., C.A. Cochrane, and S.L. Percival. The Effect of pH on the Extracellular Matrix and Biofilms. Adv Wound Care (New Rochelle). 2015. 4(7): p. 431-439. 7. Schneider, L.A., et al. Influence of pH on wound-healing: a new perspective for wound-therapy? Arch Dermatol Res. 2007. 298(9): p. 413-20. 8. B. G., et al. Proteases and pH in chronic wounds. Journal of Wound Care. 2005. 14(2): p. 59-61. 9. Leveen, H.H., et al. Chemical acidification of wounds. An adjuvant to healing and the unfavorable action of alkalinity and ammonia. Annals of surgery. 1973. 178(6): p. 745-753. 10. Das, A., et al. Monocyte and macrophage plasticity in tissue repair and regeneration. Am J Pathol. 2015. 185(10): p. 2596-606. 11. McCarty, S.M., and S.L. Percival. Proteases and Delayed Wound Healing. Adv Wound Care (New Rochelle). 2013. 2(8): p. 438-447. 12. Ghani QP, Hussain MZ, Zhang J, Hunt TK. Control of procollagen gene transcription and prolyl hydroxylase activity by poly(ADP-ribose). In: Poirier GG, Moreau P, editors. ADP-ribosylation reactions. New York: Springer-Verlag, 1992: 111-7. 13. Green H, Goldberg B. Collagen and cell protein synthesis by established mammalian fibroblast line. Nature 1964;204:347-9. 14. Hunt TK, Conolly WB, Aronson SB, Goldstein P. Anaerobic metabolism and wound healing: an hypothesis for the initiation and cessation of collagen synthesis in wounds. Am J Surg 1978;135:328-32. 9.; 15. Sheikh AY, Gibson JJ, Rollins MD, Hopf HW, Hussain Z, Hunt TK. Effect of hyperoxia on vascular endothelial growth factor levels in a wound model. Arch Surg 2000;135:1293-7. \* Data on file.