

INTRODUCTION

The fibula free flap (FFF) has allowed reconstruction of maxillary defects with vascularized osteocutaneous tissue. This gives the patient the option of dental implants in the future.¹ Plating is required to stabilize the FFF creating the neo-maxilla in line with the native maxilla. Plate complications continue to remain a long-term issue.

Virtual surgical planning (VSP) allows for improved accuracy and optimal surgical reconstruction with patient specific plates (PSP) for osseous free flaps.^{2,3}

There is currently minimal published data regarding the long-term plate-related complications of PSP used with FFF's reconstructing maxillary defects.^{3,4}

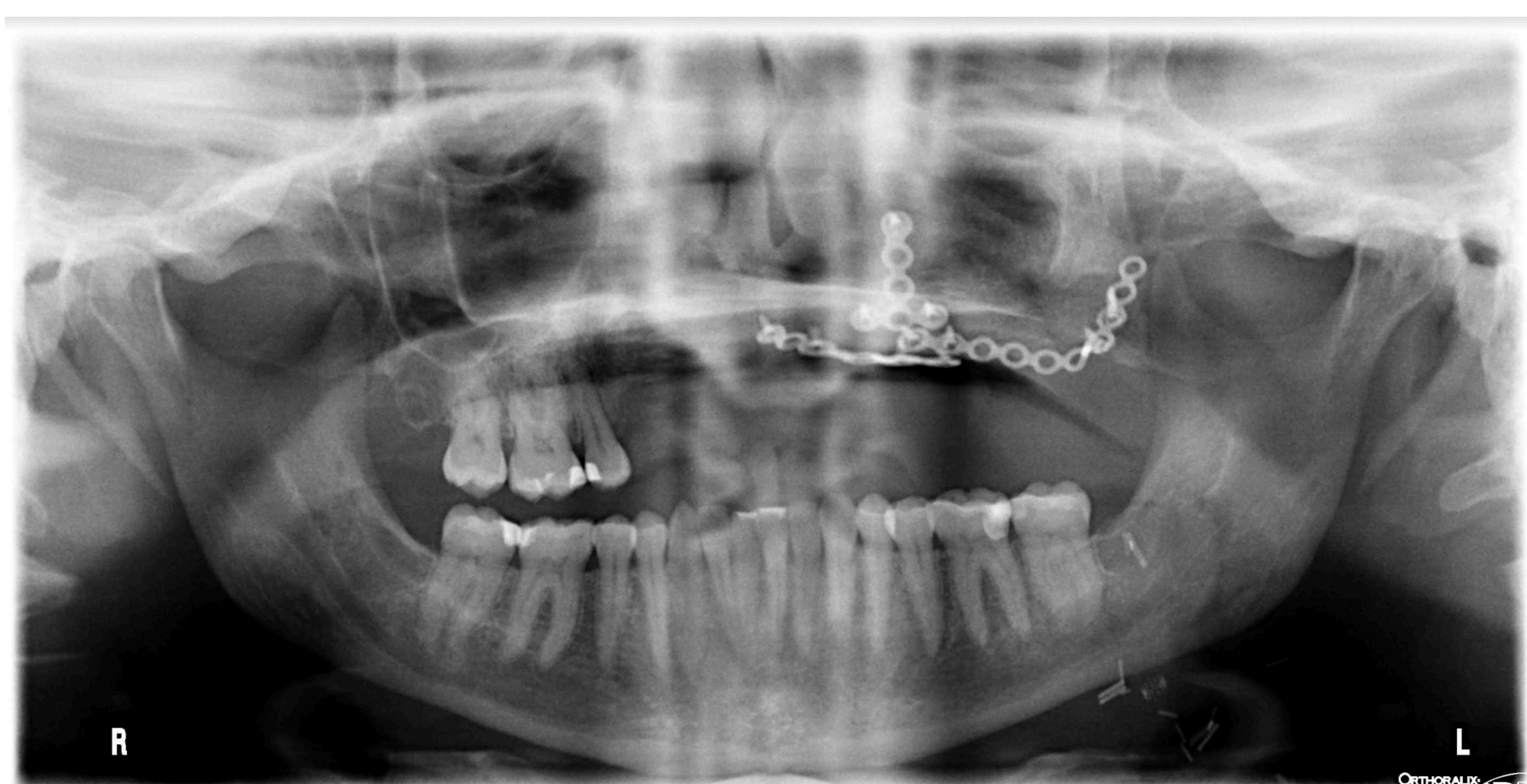

Figure 1: Panorex of a patient who has plate exposure of a segment of a FFF following maxillary reconstruction

METHODS

Retrospective chart review of patients from Jan 2010 to July 2022 who underwent reconstruction of a maxillary defect with FFF at a single tertiary care center. All patients had PSPs created during pre-operative VSP.

RESULTS

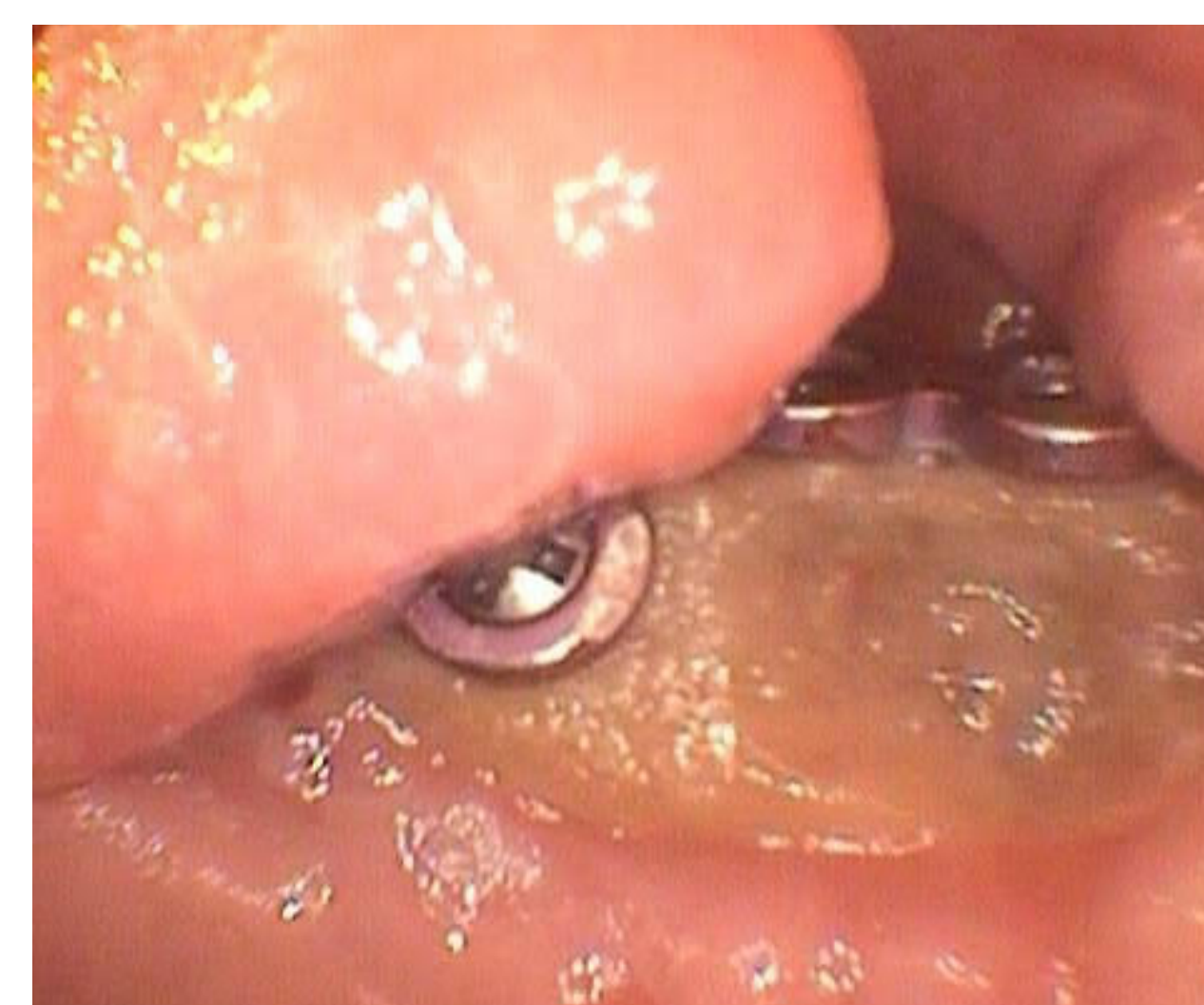
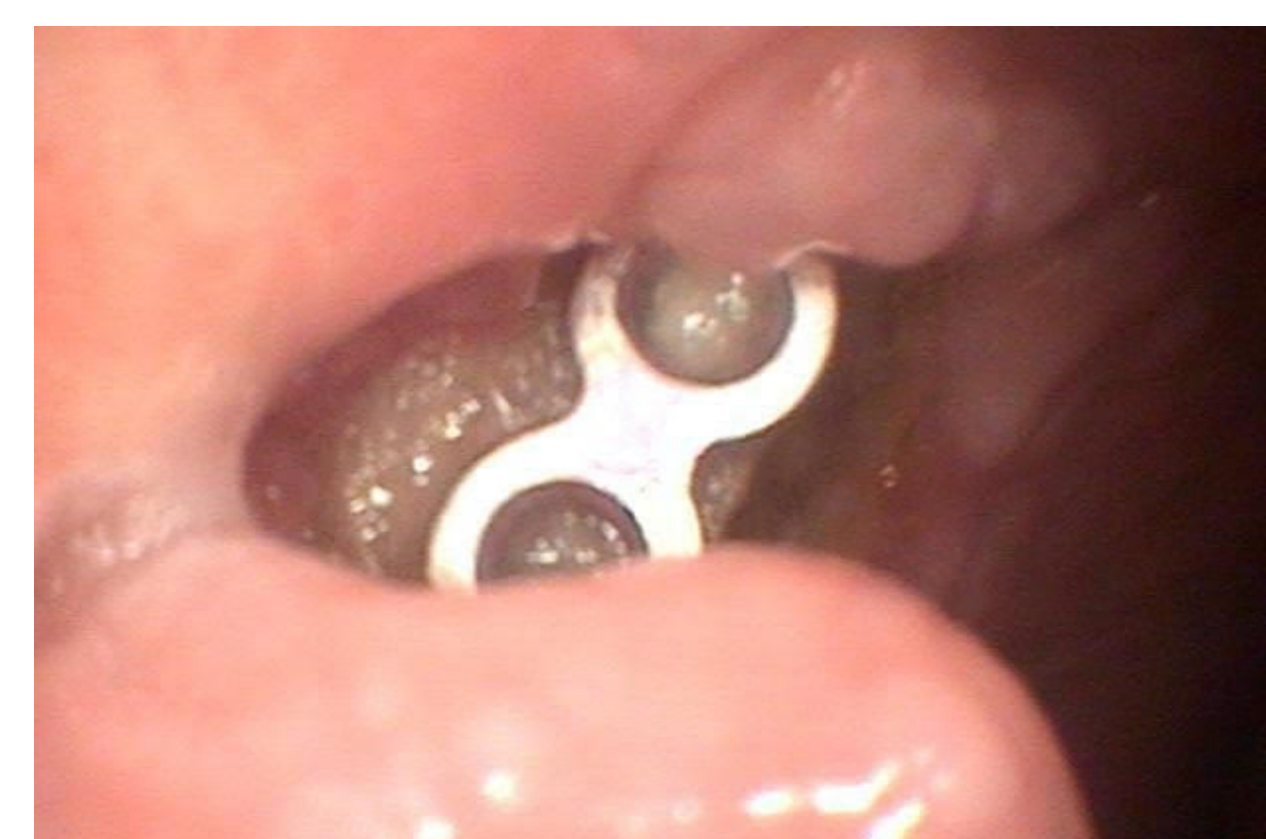
A total of 39 patients underwent PSP fibula reconstruction of maxillary defects. Average age was 57.4 + 16.9 years with an equal distribution of males to females.

The majority of the maxillary resections were due to oral cavity malignancies (n=30), with squamous cell carcinoma being the most common (46.1%, n=18). Median number of segments of the FFF created for reconstruction was 2.

Patient	Pathology	# Flap Segments	Reason for Plate Removal
1	Leiomyosarcoma	1	Recurrent infection with exposed hardware
2	Mucoepidermoid	3	Pain with loose screw
3	SCC	1	Pain with exposed hardware
4	SCC	2	Pain with exposed hardware
5	SCC	1	Exposed bone requiring hardware removal
6	Adenoid cystic	2	Exposed bone requiring hardware removal
7	Mucoepidermoid	3	Extruded plate
8	Trauma	1	Infected hardware with non-union
9	ORN	1	Exposed hardware with oroantral fistula
10	SCC	3	Hardware removed at time of tumor debulking to allow implant placement

Table 1: Case details of patients requiring plate removal

Ten plates (25.6%) were removed on average 33.6 months after initial placement. Table 1 details these cases.



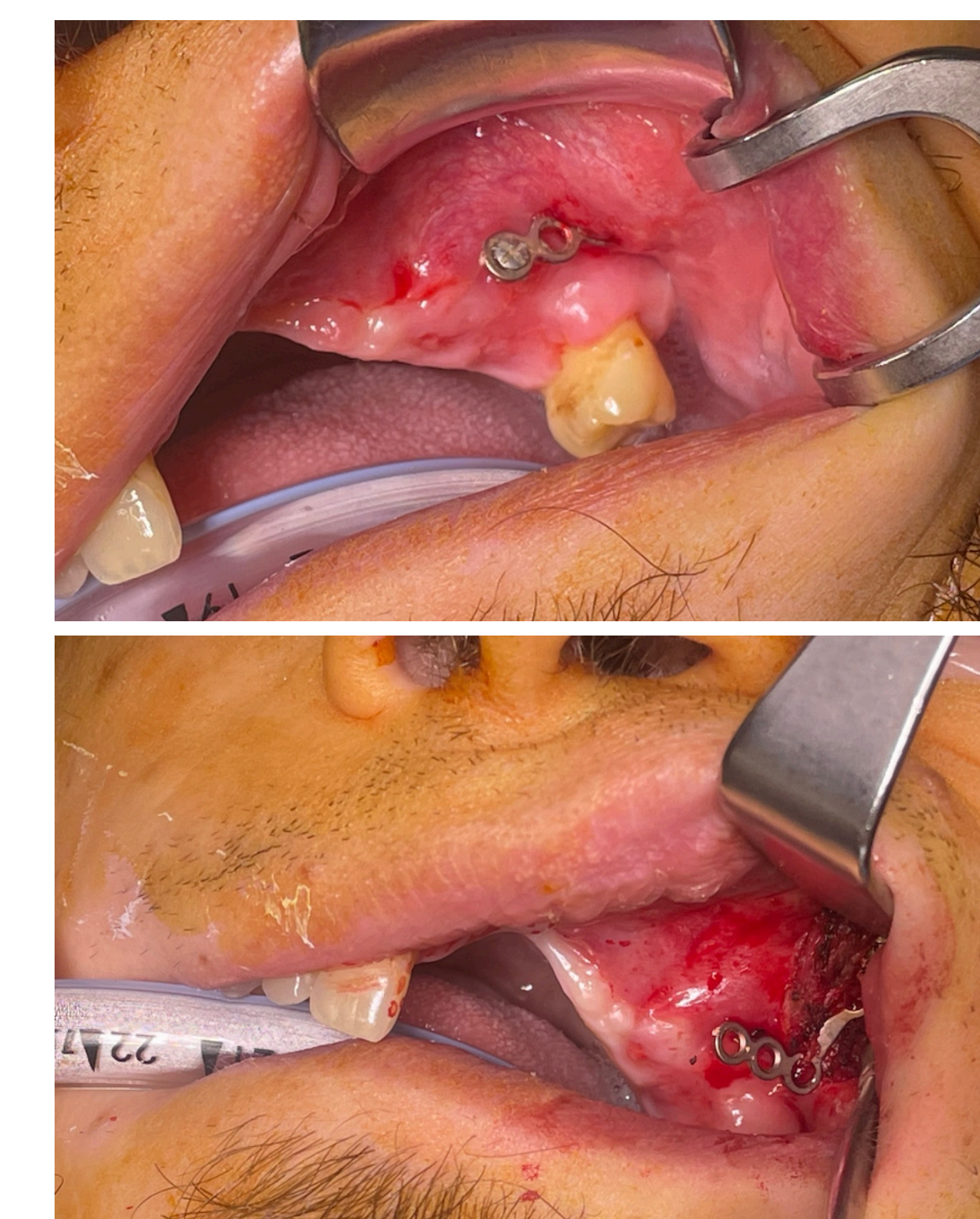Figures 2 (left, above) and 3 (left, below): Clinical photographs demonstrating intraoral bone and plate exposure in a patient who underwent FFF reconstruction of a maxillary defect

RESULTS

Complication	Number of Patients
Surgical Complications	
Wound Dehiscence	4 (10.3%)
Fistula	13 (44.8%)
Wound Infection	12 (30.8%)
Non-Union	1 (2.6%)
Flap Failure	3 (7.7%)
Plate Complications	
Plate Exposure	12 (30.8%)
Loose Screws	2 (5.1%)
Plate Fracture	0 (0%)

Table 2: Surgical and plate-related complications within the included patients and percentage of total patients

Table 2 demonstrates the surgical and plate-related complications in these patients.



Figures 4 (left, above) and 5 (left, below): Clinical photographs demonstrating intraoral plate exposure in a patient who underwent FFF reconstruction of a maxillary defect during a return trip to the operating room for plate removal

No plates were broken and only one plate required removal due to loose screws. No patients required replacement following plate removal. 18 patients had post-operative radiation therapy and this trended toward an increased risk of plate complications (OR 3.1, CI 0.68-15.88).

CONCLUSION

From our analysis, VSP appears to improve the accuracy of maxillary reconstructions with PSP and minimize plate-related complications.

CONTACT

Sara Yang, MD
Oregon Health & Science University
yangsa@ohsu.edu
509.378.8853

REFERENCES

- Peng X, Mao C, Yu GY, Guo CB, Huang MX, Zhang Y. Maxillary reconstruction with the free fibula flap. *Plast Reconstr Surg* 2005; 115:1562-1569.
- Shen Y, Li J, Ow A, Wang L, Lv MM, Sun J. Acceptable clinical outcomes and recommended reconstructive strategies for secondary maxillary reconstruction with vascularized fibula osteomyocutaneous flap: A retrospective analysis. *J Plast Reconstr Aesthet Surg* 2017; 70:341-351.
- Chan TJ, Long C, Wang E, Prisman E. The state of virtual surgical planning in maxillary Reconstruction: A systematic review. *Oral Oncol* 2022; 133:106058.
- Futran ND, Wadsworth JT, Villaret D, Farwell DG. Midface reconstruction with the fibula free flap. *Arch Otolaryngol Head Neck Surg* 2002; 128:161-166.