

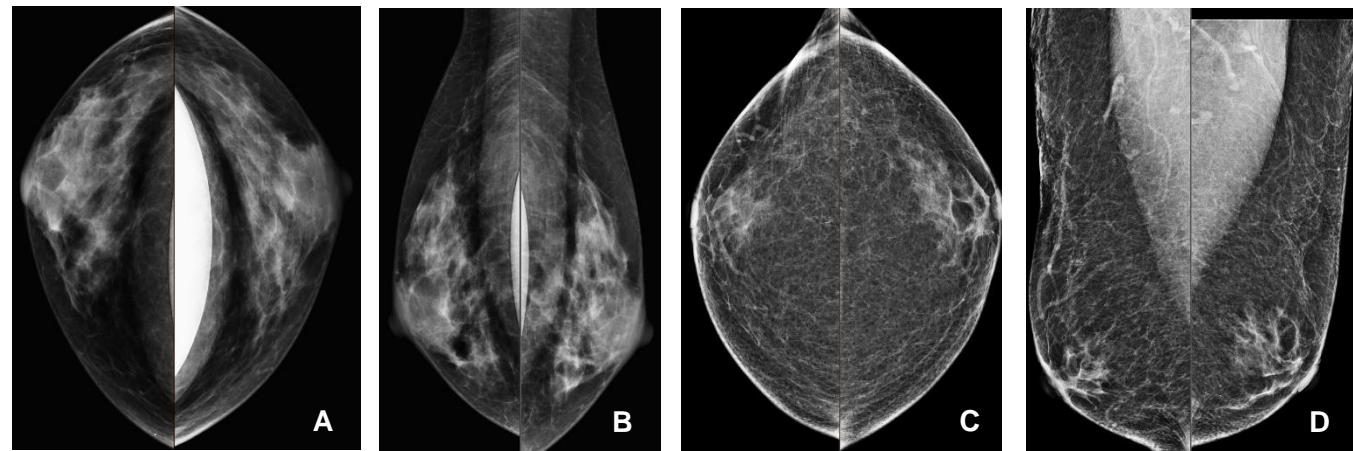
# Current Trends and Guidelines for Breast Cancer Screening in Transgender Patients

Cameron J Overfield, Justin Stowell, Haley Letter  
Department of Radiology, Mayo Clinic, Jacksonville, FL

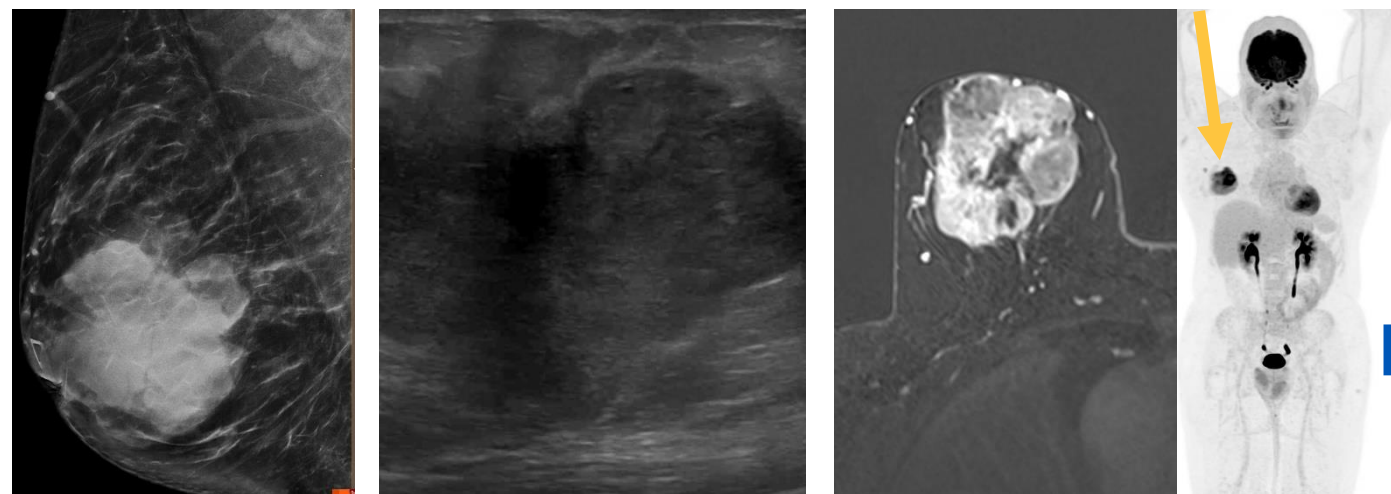## INTRODUCTION

It is increasingly important for radiologists to be aware of the current guidelines and evidence-based transgender care, especially for breast cancer screening. For example, most transfeminine patients (assigned male sex at birth with feminine gender identity) who receive feminizing hormones (usually estrogen and antiandrogens) will develop either heterogeneously dense or extremely dense breast tissue, increasing the risk of breast cancer. A review of the most up to date guidelines and trends in transgender breast cancer screening was performed.

Transfeminine patients who receive feminizing hormones may be at increased risk of breast cancer, with one recent cohort study showing a 46-fold higher incidence compared to cisgender men (assigned male sex at birth with male gender identity). In transmasculine patients (assigned female sex at birth with masculine gender identity), testosterone leads to reduction in active glandular tissue and increased stromal hyalinization but has not been associated with higher or lower rates of breast cancer. Transmasculine patients who undergo chest masculinization surgery to achieve a masculine chest contour have lower rates of breast cancer than cisgender women (assigned female sex at birth and identify as women).



Normal screening mammogram A) CC and B) MLO views of a 50-year-old transfeminine patient on feminizing hormones C) CC and D) MLO views of a 50-year-old transfeminine patient without feminizing hormones with retroareolar glandular tissue consistent with gynecomastia.



## US PREVENTATIVE SERVICES TASK FORCE (USPSTF)

- Currently, the USPSTF guidelines lack clarity and use gender terms inconsistently and interchangeably
- When it refers to “women aged 40 years or older” it is unclear whether it applies to persons assigned female sex at birth only or includes intersex and transgender individuals with breasts.
- Pilot strategies are being tested to address sex and gender diversity.
- No specific recommendations are available that apply to transmasculine and transfeminine patients.

## ACR APPROPRIATENESS CRITERIA

1. Transfeminine (male-to-female) patient, 40 years of age or older with past or current hormone use equal to or greater than 5 years. Average risk patient. = **Mammography screening May Be Appropriate**
2. Transfeminine patient 25 to 30 years of age or older with past or current hormone use equal to or greater than 5 years. Higher-than-average risk. = **Mammography screening is Usually Appropriate**
3. Transfeminine patient with no hormone use (or hormone use less than 5 years) at any age. Average-risk patient. = **Mammography screening is Usually NOT Appropriate**
4. Transfeminine patient, 25 to 30 years of age or older with no hormone use (or hormone use less than 5 years). Higher-than-average risk. = **Mammography screening May Be Appropriate**
5. Transmasculine (female-to-male) patient with bilateral mastectomies at any age and any risk. = **Mammography screening is Usually Not Appropriate**
6. Transmasculine patient with reduction mammoplasty or no chest surgery, 40 years of age or older. Average-risk patient. = **Mammography screening is Usually Appropriate**
7. Transmasculine patient with reduction mammoplasty or no chest surgery, 30 years of age or older. Intermediate risk. = **Mammography screening is Usually Appropriate AND US breast OR MRI breast without and with IV contrast May Be Appropriate**
8. Transmasculine patient with reduction mammoplasty or no chest surgery, 25-30 years of age or older. High risk. **Mammography screening AND MRI breast without and with IV contrast are Usually Appropriate; US breast May Be Appropriate**

39-year-old transfeminine patient on feminizing hormones estradiol/spironolactone for 3 years who presents with a palpable right breast mass A) MLO mammographic image demonstrates a large breast mass B) Grayscale ultrasound image demonstrates the hypoechoic, ill-defined mass C) Subtraction MRI shows central necrosis with peripheral enhancement D) PET rotating MIP image shows the mass (arrow) to be hypermetabolic in the right breast.

## DISCUSSION

- A wide array of benign and malignant pathology may be encountered in transgender women like those found in cisgender women including cysts and fibroadenomas.
- In 2022, Oladeru et al. found that common barriers to screening adherence include expensive medical costs, access to primary care providers, and denial of coverage from insurance companies. Along similar lines, medical training has not traditionally included a curriculum on transgender health for which medical providers may be unaware of the unique health disparities and screening recommendations that exist in this patient population. Data shows that patients are more likely to be screened if recommended by a healthcare professional.

## CONCLUSIONS

- Barriers to screening recommendations increase transgender healthcare disparities and ultimately contribute to poor health outcomes.
- Current evidence and guidelines support an organized approach to transgender breast cancer screening. The authors propose a risk assessment and stratification at age 25 for all transgender patients. Thereafter, screening should be recommended based on age, prior surgeries, and/or hormone use.

## REFERENCES

1. Caughey AB, Krist AH, Wolff TA, et al. USPSTF Approach to Addressing Sex and Gender When Making Recommendations for Clinical Preventive Services. JAMA. 2021;326(19):1953–1961.
2. Expert Panel on Breast Imaging; Brown A, Lourenco AP, Niell BL, Cronin B, Dibble EH, DiNome ML, Goel MS, Hansen J, Heller SL, Jochelson MS, Karrington B, Klein KA, Mehta TS, Newell MS, Schechter L, Stuckey AR, Swain ME, Tseng J, Tuscano DS, Moy L. ACR Appropriateness Criteria® Transgender Breast Cancer Screening. J Am Coll Radiol. 2021 Nov;18(11S):S502-S515.