Application of a Novel Meshed Human Reticular Acellular Dermal Matrix* Supports Lower Extremity Wound Closure

[1,2]Joseph Larsen, DPM, DABFAS

[1]Chair of Podiatry, Optum Podiatry, [2]Attending Physician, New York Presbyterian Weil Cornell Medical Center

INTRODUCTION

Soft tissue defects can lead to infection, delayed healing, and other post-operative complications. A ready-to-use, off-the-shelf, pre-hydrated option, is meshed human reticular, acellular dermal matrix (HR-ADM) that provides a scaffold for native soft tissue restoration. The open architecture of the reticular dermal layer in meshed HR-ADM supports cell infiltration and graft integration. The tissue form is intended for supplemental support to the underlying dermal matrix as the result of damage due to resection or debridement, or naturally occurring defects. This current study is a 3-patient case-series examining the application of meshed HR-ADM for the treatment of a traumatic leg injury, ulcer from a revision TMA, and a heel ulcer.

METHODS

Meshed HR-ADM was applied to ulceration sites after thorough surgical debridement and secured in place. Negative pressure wound therapy (NPWT) was utilized when clinically appropriate, while bolster dressings were used when NPWT was not utilized. Weekly assessment and standard treatment protocols were followed until complete closure was achieved.

RESULTS

In all three cases, robust granulation was observed, and graft integration, which led to wound closure despite challenging patient co-morbidities. The meshed HR-ADM provided a dermal foundation that vascularized and incorporated, culminating in full closure without multiple visits to the OR. This can lead to reduced costs and risks with surgery.

DISCUSSION

Meshed HR-ADM provided a native dermal scaffold to support host cell infiltration and build healthy, organized and robust granulation tissue. These observations demonstrate the reticular dermal allograft matrix can support post-surgical deficits by providing a solid dermal foundation and resulting in effective subsequent re-epithelialization. Use of HR-ADM can support wound closure, decrease the likelihood of post-operative complications and reduce medical costs.

***SomaGen® (MTF Biologics, Edison, NJ)**

CASE STUDIES

CASE STUDY 1 - Ulcer from Revision TMA

Initial Examination/History: 91 yr old male with OM of the left foot with non-healing wound. Post 2nd toe amputation- non healing with Osteomyelitis. PMH/Risk factors - DM, CAD, PVD,

Treatment: TMA- with ulcer and infection- revision of TMA, open TMA with initial meshed HR-ADM application completed on 2/15/22. Recurrent wound with Osteomyelitis. 2nd revision on 3/3/22

Outcome: Wound closed wih 2 applications of meshed HR-ADM.

Figure 1A. Wound at initial presentation (Day 0)

Figure 1B. Application of meshed HR-ADM (Day 0)

Figure 1C. Less depth, sent for debridement and re-grafting (2 Weeks)

Figure 1D. Post-debridement healthy wound; Application of meshed HR-ADM (2 Weeks)

Figure 1E. Graft incorporation (4 Weeks)

Figure 1F. Wound granulation with edges contracting (24 Weeks)

Figure 1G. Wound further reduced in size (26 Weeks)

Figure 1H. Wound Closed (8.5 Months)

CASE STUDY 2 — Traumatic Leg Wound

Initial Examination/History: 70 yr old female, DVT on Xarelto, COPD, multiple myeloma, CVA, AKI, stroke. Patient arrived to ED (7/1/20) after sustaining a fall missing a step of walking into a bus. Patient lacerated skin full thickness to left anterior skiin. Laceration was repaired with absorbable sutures. Patient arrived again to ED (7/13/20), 12 days later for left arm weakness facial droop. Podiatry consulted for left leg cellulitis and wound. Sutures were removed due to dehiscence and erythema. X-rays and MRI.

Treatment: Patient was placed on IV antibiotics and wound was dressed with bacitracin dsd. Derm: distal 1/3 tibia 12.3 x1.4cm2 wound ecchymosis and erythema. Necrotic eschar overlying a fibrotic base observed. No purulence or fluctuance. Culture swab revealed 4 types of aerobic/anaerobic bacteria (7/15/20). Started broad spectrum antibiotics, Bactrim, Levaquin 10 day course. Meshed HR-ADM graft applied (7/20/20) and patient seen weekly in podiatry clinic for wound care.

Outcome: 8 weeks fully healed, applied Unna boot b/l for edema control (also on furosemide). Patient still healed Oct 2020 with compressive stockings for edema control 15 months f/U. Patient last seen 3/24/22. C/o left anterior leg with cicatrix. Continued compression stockings, seeing vascular clinician, lidex rx for cicatrix.

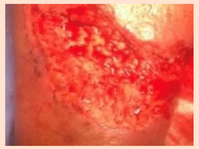

Figure 2A. Wound at initial presentation

Figure 2B. Application of meshed HR-ADM (Day 0)

Figure 2C. Graft in place (2 Weeks)

Figure 2D. Debrided with 4mm curette (4 Weeks)

Figure 2E. Compression dressings applied (6 Weeks)

Figure 2F. Compression dressings applied with MediHoney (7 Weeks)

Figure 2G. Fully healed, Unna boot applied (8.5 Weeks)

Figure 2H. Remained fully healed (15 month F/U)

CASE STUDY 3 — Heel Ulcer

Initial Examination/History: 55 yr old male, Seen in hospital with a non-healing left heel ulcer with osteomyelitis, left calcaneus. PMH- DM,ESRD on Dialysis, Right BKA, PAD with previous LE angioplasty.

Treatment: Debridement, bone biopsy, antibiotics, meshed HR-ADM application, non-weight bearing, off loading multi-podos boots.

Outcome: Wound closed. After healing, an ambulating custom shoe was used.

Figure 3A. Wound at initial presentation

Figure 3B. Debridement and bone biopsy, 3.5 cm x 3.0 cm

Figure 3C. Application of Meshed HR-ADM (Day 0)

Figure 3D. 2.5 cm x 1.0 cm (2 Months)

Figure 3E. 1.0 cm x 0.5 cm (3 Months)

Figure 3F. Wound closed (4 Months)