The Healing Power of Nature

Treatment of hard to heal Venous Leg Ulcers with Fish Skin Graft* in Geriatric Patients

Roland A. Tolliver, DPM, FAPWCA, FACFS

Center for Wound Healing at FHN, Freeport, IL

kerecis®

INTRODUCTION

Venous leg ulcers (VLU) are painful, often debilitating, and a significant economic healthcare burden1. VLUs result from venous hypertension secondary to reflux and in combination with obstruction2. Along with morbidity, age is a significant risk factor for developing VLUs, and often treatment is unsuccessful. Managing the underlying pathophysiology is critical to healing VLUs; however, fish skin grafts can augment the healing of chronic VLUs in patients with high morbidity3. The primary purpose of this case series was to investigate fish skin for the treatment of hard-to-heal VLUs and, secondarily, to evaluate pain subjectively.

METHODS

CASE 1:
Patient 1 is an 82-year-old female that presented with extensive venous hypertension with inflammation and bilateral ulcerations. Before coming to our clinic, she underwent nine months of unsuccessful treatment where the ulcerations made little progress. The decision was made to debride the ulcers surgically, and micronized and meshed fish skin was applied. The patient was referred to the Wound Care center for continued treatment with fish skin grafts.

CASE 2:
Patient 2 is an 84-year-old-male with extensive ulcerations to the left leg accompanied by chronic pain and drainage. The patient complained of debilitating pain and stated he could only sleep in a recliner. He underwent surgical debridement and application of micronized and meshed fish skin.

RESULTS

CASE 1:
The wound size and appearance improved with each visit and treatment with the fish skin graft. There was significant bilateral drainage that required twice daily dressing changes. Interestingly, the patient went from chronic, near-constant pain to minimal pain with the treatment of a fish skin graft.

CASE 2:
The patient stated he experienced a significant decrease in pain almost immediately after the initial fish skin treatment. The patient has undergone several fish skin grafts at the Wound Care Center with continued improvement, decreased drainage, and diminished pain.

*Kerecis™, Kerecis, Isafjordur, Iceland

CASE: 82-YEAR-OLD FEMALE BILATERAL ULCERATIONS

Patient History: 82-year-old female with extensive venous hypertension with inflammation

Wound History: Patient presented with bilateral ulcerations and had undergone nine months of unsuccessful treatment where ulcers made little progress

Kerecis Applications: Multiple applications of fragmented and meshed intact fish skin graft in office and OR setting

Patient Outcomes: Good healing progression seen at 6 weeks and wound size and appearance improved at each follow up visit

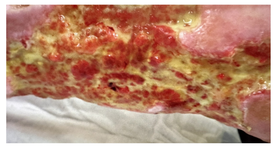
Initial presentation pre-debridement

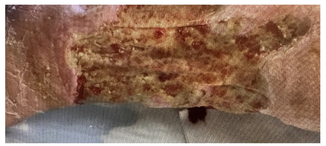
Week 1 Follow up

Week 3 Follow up

Week 6 Follow up

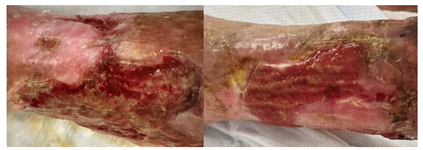
Week 12 Follow up

Application of fish skin graft in OR

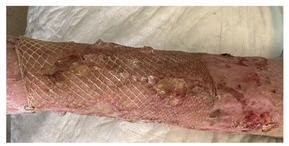
Week 16 Follow up

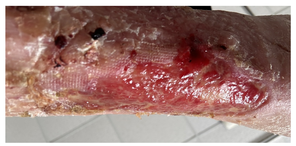
Week 28 Follow up

Week 32 Follow up

Fish skin graft fully incorporated and wounds have decreased significantly in size

CASE: 84-YEAR-OLD MALE LEFT LEG ULCERATION

Patient History: 84-year-old male with chronic pain and drainage

Wound History: Patient presented with extensive ulcerations to the left leg and complained of debilitating pain where he could only sleep in a reclincer

Kerecis Applications: Multiple applications of fragmented and meshed intact fish skin graft I

Patient Outcomes: Good healing progression with wound almost completely healed at 7 months

Initial presentation pre-debridement

Week 2 Follow up

Week 5 Follow up

Week 11 Follow up
Fish skin graft fully incorporated

Week 12 Application of fish skin graft in OR

DISCUSSION

Chronic VLUs are painful and debilitating and often present with delayed wound healing1,2,3. Fish skin is minimally processed by way of osmotic mechanisms, which preserves its native dermal architecture and biomechanical and chemical composition resulting in superior acute and chronic wound healing4,5,6. In this small case series, the fish skin successfully treated chronic VLUs in geriatric male and female patients and provided a strong analgesic effect.

References

1. Lal BK. Venous ulcers of the lower extremity: Definition, epidemiology, and economic and social burdens. Semin Vasc Surg. 2015 Mar;28(1):3-5. doi: 10.1053/j.semvascsurg.2015.05.002. Epub 2015 May 8. PMID: 26358303.
2. Melikian, R., O'Donnell, T. F., Jr, Suarez, L., & Iafrati, M. D. (2019). Risk factors associated with the venous leg ulcer that fails to heal after 1 year of treatment. Journal of vascular surgery. Venous and lymphatic disorders, 7(1), 98–105. https://doi.org/10.1016/j.jvsv.2018.07.014
3. Yang CK, Polanco TO, Lantis JC 2nd. A Prospective, Postmarket, Compassionate Clinical Evaluation of a Novel Acellular Fish-skin Graft Which Contains Omega-3 Fatty Acids for the Closure of Hard-to-heal Lower Extremity Chronic Ulcers. Wounds. 2016 Apr;28(4):112-8. PMID: 27071138
4. Magnusson S, Baldursson BT, Kjartansson H, Rolfsson O, Sigurjonsson GF. Regenerative and Antibacterial Properties of Acellular Fish Skin Grafts and Human Amnion/Chorion Membrane: Implications for Tissue Preservation in Combat Casualty Care. Mil Med. 2017 Mar;182(S1):383-388. doi: 10.7205/MILMED-D-16-00142. PMID: 28291503.
5. Kirsner, R. S., Margolis, D. J., Baldursson, B. T., Petursdottir, K., Davidsson, O. B., Weir, D., & Lantis, J. C., 2nd (2020). Fish skin grafts compared to human amnion/chorion membrane allografts: A double-blind, prospective, randomized clinical trial of acute wound healing. Wound repair and regeneration : official publication of the Wound Healing Society [and] the European Tissue Repair Society, 28(1), 75–80. https://doi.org/10.1111/wrr.12761
6. Lullove, E. J., Liden, B., Winters, C., McEneaney, P., Raphael, A., & JC, L. I. (2021). A Multicenter, Blinded, Randomized Controlled Clinical Trial Evaluating the Effect of Omega-3-Rich Fish Skin in the Treatment of Chronic, Nonresponsive Diabetic Foot Ulcers. Wounds: a Compendium of Clinical Research and Practice.