The Healing Power of Nature

Fish Skin Graft* (FSG) for the treatment of post-Mohs wound of the nose

Courtney Aldridge PA-C and Ryan P. O'Quinn, MD

South Texas Skin Cancer Center, San Antonio, TX

INTRODUCTION

PPost-Mohs wounds on the nose can be cosmetically and functionally difficult to manage. These wounds can be more complicated when scar tissue from previous procedures is also present. Exposed cartilage, an avascular structure, limits repair options for more advanced surgical wounds. Cosmesis is always a concern when dealing with facial repairs. Maintaining a patent airway and avoiding tension on the lower eyelid, causing an ectropion, are critical points when designing a functional repair. Fish Skin Graft (FSG) can be used to help generate granulation tissue to cover cartilage and fill volume loss to enhance cosmetic and functional results. FSG will also prevent or slow the contraction of a wound to reduce ectropion risk.

METHODS

An eighty-nine-year-old female presented with a 1.5cm x 1.3cm basal cell carcinoma on the right nasal side wall, present for greater than one year. She had previous skin cancer treated in the same area several years ago by another physician with visible scarring from skin grafting. The basal cell carcinoma was cleared after six Mohs layers resulting in a 5.0cm x 4.5cm wound with exposed cartilage. Layered FSG (19 sq cm micro and 3cm x 7cm sheet) was used in the initial phase of the reconstruction. A second application of FSG (38sq cm micro) was used a week later. A final FSG (19 sq cm micro) was applied two-weeks post Mohs surgery to achieve a healthy granulation bed flush with the wound edge. A full thickness skin graft was applied four weeks post Mohs surgery so that the family and patient could minimize follow up visits.

*Kerecis™, Kerecis, Isafjordur, Iceland

CASE # 1: 89-YEAR-OLD FEMALE BASAL CELL CARCINOMA

Patient History: 89-year-old female with COPD, anxiety, and hypertension presented with a recurrent BCC in the right nasal sidewall extending to the nasal tip.

Wound History: Patient presented with a 1.5cmx1.3cm basal cell carcinoma on the right side of the nasal wall present for greater than one year. Patient had previous skin cancer treated in the same area several years prior.

Fish Skin Graft Applications: 3 Applications of intact fish skin graft

PATIENT OUTCOMES:

1.5 x 1.3 cm wound on the right side of the nasal wall prior to Mohs surgical excision

5.0cm x 4.5cm wound with exposed cartilage following Mohs surgical excision of a basal cell carcinoma (BCC)

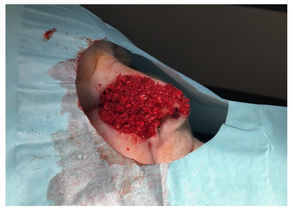

Application of micronized FSG with wound blood

Application of FSG sheet over micronized FSG

Two weeks post application

Micronized FSG with serum blood mixture

One week post application

Full thickness skin graft

FISH SKIN GRAFT APPLICATIONS

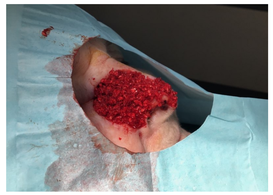

RESULTS

The FSG allowed granulation tissue to cover exposed cartilage and fill volume loss without excessive contraction enhancing both cosmetic and functional results. Only three applications of FSG were needed to simplify the reconstruction of this large post Mohs surgical defect. The patient reported zero pain or irritation during the healing process.

DISCUSSION

Designing reconstructive plans for fragile elderly patients that are both functional and cosmetic in design can be challenging when the defect is large post Mohs surgery in the nasal area. FSG allows significant wound healing so the final reconstruction can be simplified. The FGS provided anti-inflammatory benefits from omega-3-rich fatty acids and decreased the infection potential during the healing process. The FSG also provided the necessary granulation scaffold needed to increase the viability of a full thickness skin graft without excessive wound contracture.

References

1. Liu, Katherine Y. BAa; Silvestri, Brittni PAa; Marquez, Jocellie MD, MBAb; Huston, Tara L. MD, FACSa. Secondary Intention Healing After Mohs Surgical Excision as an Alternative to Surgical Repair: Evaluation of Wound Characteristics and Esthetic Outcomes. Annals of Plastic Surgery 85(S1):p S28-S32, July 2020. | DOI: 10.1097/SAP.0000000000002330
2. Stone, R., Saathoff, E. C., Larson, D. A., Wall, J. T., Wienandt, N. A., Magnusson, S., ... & Christy, R. J. (2021). Accelerated wound closure of deep partial thickness burns with acellular fish skin graft. International Journal of Molecular Sciences, 22(4), 1590.
3. Seth, N. E. I. L., Chopra, D. I. V. Y. A., & Lev-Tov, H. (2022). Fish skin grafts with omega-3 for treatment of chronic wounds: exploring the role of omega-3 fatty acids in wound healing and a review of clinical healing outcomes. Surg Technol Int, 40, 38-46.