The Healing Power of Nature

Definitive wound closure of a large scalp Mohs defect with exposed cranium in an irradiated field utilizing a fish skin xenograft

Mark Suski, MD, FACS

Los Robles Regional Medical Center, Department of Plastic Surgery, Thousand Oaks, CA

kerecis®

INTRODUCTION

Moh's micrographic surgery is a tissue-sparing technique used to treat nonmelanoma skin cancers. Reconstruction of soft tissue defects after Moh's surgery can be a substantial challenge Factors that exacerbate the clinical challenge include gender, modifiable risk factors, diabetes mellitus, size and severity of the defects, and the complexity of the reconstructive modality1. In wounds with the exposed underlying bone, there are limited reconstructive options. The closure could be further complicated if the area received prior radiation therapy due to insufficient blood supply, fibrosis, and attenuated cellular function2. To this end, advanced biologics, including a fish skin graft, are often warranted. This investigation aimed to determine the clinical efficacy of fish skin in this subset of challenging patients.

METHODS

The patient is a 78-year-old white female who was status post resection of a right parietal scalp sarcoma with a titanium plate cranioplasty and rotation flap reconstruction approximately ten years ago. Her surgery was followed by adjuvant radiation therapy. Past medical history is pertinent for noninsulin-dependent diabetes mellitus and venous thromboembolism, requiring active anticoagulation. In July 2022, the patient underwent Moh's excision for a poorly differentiated squamous cell carcinoma of her vertex scalp within the prior radiation field. It required multiple passes for definitive oncological clearance. The final excision resulted in a 7 by 5 cm defect with an exposed cranium. The following day, she was taken to the OR for bone burring and omega-3 fish skin xenograft placement. A nonadherent compressive postoperative dressing was applied, and the patient's anticoagulation was restarted on postoperative day #1.

CASE: 78-YEAR-OLD FEMALE SQUAMOUS CELL CARCINOMA (SCC)

Patient History: 78-year-old female with past medical history pertinent for noninsulin-dependent diabetes mellitus and venous thromboembolism

Wound History: Patient was status post resection of a right parietal scalp sarcoma with a titanium plate cranioplasty and rotation flap reconstruction 10 years prior. Pt presented with a surgical wound following Mohs excision of squamous cell carcinoma (SCC) resulting in a 7.0x5.0cm defect with exposed cranium

Fish Skin Graft Applications: 8 Applications of fish skin graft at weekly or biweekly intervals

Patient Outcomes: Complete healing with no complications and excellent cosmetic outcome without the need of a staged surgical reconstruction

7.0 x 5.0 cm wound to the level of the bone (calvarium) following Mohs surgical excision of a squamous cell carcinoma (SCC)

Post-debridement prior to initial application of fish skin graft

Application of fish skin graft to cover exposed bone

Week 2 Post op

Week 3 Post op

Week 4 Post op

Week 6 Post op

Week 12 Post op

Following 8 applications of the fish skin graft, wound reached 100% closure

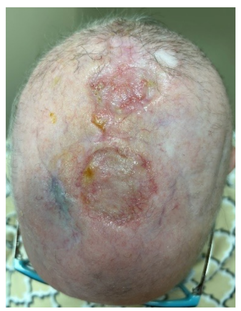

Anterior wound healed with graft and posterior wound healed with FSG

RESULTS

After eight applications of the fish skin xenograft at weekly or biweekly intervals, the wound completely healed without needing a staged surgical reconstruction.

DISCUSSION

Omega 3 fish skin xenografts are FDA approved for treating chronic and acute surgical wounds3,4. The product is an acellular dermal matrix harvested from Icelandic cod with a porous microstructure like human skin. Characteristics of the xenograft include bacterial resistance, angiogenesis, and inflammatory cytokine mitigation5. This case report shows that a fish skin xenograft is suitable for complex wound closure, including difficult Moh's reconstruction.

References

1. Miller, M. Q., David, A. P., McLean, J. E., Park, S. S., & Christophel, J. (2018). Association of Mohs Reconstructive Surgery Timing With Postoperative Complications. JAMA facial plastic surgery, 20(2), 122–127. https://doi.org/10.1001/jamafacial.2017.1154
2. Hoang, T. T., Vu, V. Q., & Trinh, D. T. (2019). Management of radiation-induced ulcers by singlestage reconstructive surgery: a prospective study. Annals of burns and fire disasters, 32(4), 294–300.
3. Baldursson BT, Kjartansson H, Konráðsdóttir F, Gudnason P, Sigurjonsson GF, Lund SH. Healing rate and autoimmune safety of full-thickness wounds treated with fish skin acellular dermal matrix versus porcine small-intestine submucosa: a noninferiority study. Int J Low Extrem Wounds. 2015 Mar;14(1):37-43. doi: 10.1177/1534734615573661. Epub 2015 Mar 9. PMID: 25759413.
4. Lullove, E. J., Liden, B., Winters, C., McEneaney, P., Raphael, A., & JC, L. I. (2021). A Multicenter, Blinded, Randomized Controlled Clinical Trial Evaluating the Effect of Omega-3-Rich Fish Skin in the Treatment of Chronic, Nonresponsive Diabetic Foot Ulcers. Wounds: a Compendium of Clinical Research and Practice.
5. Magnusson S, Baldursson BT, Kjartansson H, Rolfsson O, Sigurjonsson GF. Regenerative and Antibacterial Properties of Acellular Fish Skin Grafts and Human Amnion/Chorion Membrane: Implications for Tissue Preservation in Combat Casualty Care. Mil Med. 2017 Mar;182(S1):383-388. doi: 10.7205/MILMED-D-16-00142. PMID: 28291503.