The Healing Power of Nature

The Application of Piscine Acellular Dermal Matrix* (PADM) in surgical reconstruction and salvage

Charles Marchese, DPM, FAPWH

Manalapan Foot & Ankle, Manalapan, NJ

kerecis®

INTRODUCTION

Surgical wounds are synonymous with traumatic wounds with regards to their tissue needs. Whatever the etiology; ischemia, frank trauma, metabolic, phlebolymphodema, amputation, the resulting wounds have common characteristics and requirements that need to be met to regenerate tissue and heal. The resultant wound demands that need to be addressed; tissue defect, exposed structure, infection and contamination, diminished vascularity, disorganized cells, a paucity of cells, inflammation and pain.

The ideal CTP (cellular tissue product) should address these exigencies and do so with minimal immune host response and without concern for rejection .PADM (Piscine Acellular Dermal Matrix) has been proven to meet the needs of the surgical or traumatic wound and regenerate tissue and expedite healing in these complex wounds sooner and more effectively and with better tissue.

RESULTS

The PADM applied in these cases presented has a macrostructure with a physically robust integrity that covers exposed structure and tissue deficit. It posses a microstructure that is more favorable than human amniotic membrane that provides for ingrowth of cells, neo vascularization and cell adhesion, making it an ideal lattice platform for tissue replacement. It is immunogenic and elicits no host response or rejection. It provides for cell organization (via cell adhesion on its favorable lattice) and it possesses the macromolecules, factors, and cells that through its paracrine effect orchestrates tissue replacement and formation.

DISCUSSION

The ethology of surgical wounds can be; frank trauma, the result of ischemia, metabolic disease, the poor tissue of phlebolymphodema that leads to tissue loss, tissue loss secondary to infection , post amputation wounds or wounds of salvage procedures. Whatever the etiology, the resultant tissue defect has complex characteristics that need to be addressed to regenerate tissue and heal. The characteristics are similar in that there is often tissue deficit and loss, there is a degree of contamination and infection, they are painful, there is a paucity of vascular structure and diminished circulation, tissue is lacking the structure needed to establish a platform on which tissue growth and the cells needed to heal can organize ,and the cells are lacking or senescent.

The extracellular matrix is essential to heal wounds. ECM bio scaffolds play an essential role in tissue reconstruction and replacement. These bio scaffolds provide a lattice that maintain macromolecules, tissue factors and cells that through the paracrine effect recruit, communicate and organize necessary host cells that will promote tissue replacement.

The application of PADM in surgical salvage and reconstruction plays a pivotal role in regeneration of tissue by providing a lattice that maintains the macromolecules, factors, and cells that provide for tissue growth and help heal these complex deficits characteristically encountered in salvage whatever the etiology by addressing all their needs.

In addition, it possesses Omega 3 and fatty acids that provides an anti infective anti-inflammatory and Analgesic effect. It also will move the wound from the inflammatory phase of healing that these wounds are often "stuck" in , by increasing signaling activity for concluding the inflammatory phase of wound healing.

*Kerecis™, Kerecis, Isafjordur, Iceland

CASE 1: 60-YEAR-OLD FEMALE LIMB SALVAGE

Patient History: 60 year old female presented after d/c from short term care facility with significant edema and tissue loss. Hypertension, venous insufficiency lymphedema, arthritis.

Wound History: patient s/p severe phlebolymphadema poorly managed with significant tissue defect, after managing edema with intermittent compression, compression therapy including URGO 2 MLC and diuresis patient stabilized for graft application.

Fish Skin Graft Applications: 11 applications over 19 weeks

Patient Outcomes: After 11 applications patient wounds are epithelized almost 100%

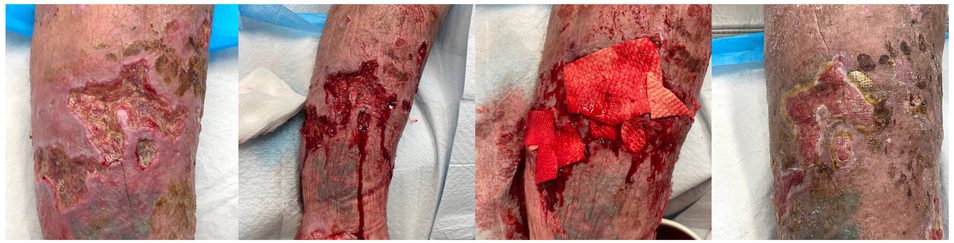

Initial presentation | Post debridement | Application of piscine acellular dermal matrix | Week 19

CASE 2: 60 -YEAR-OLD MALE LIMB SALVAGE

Patient History: 60 yo male s/p amputation for OM hallux with necrotizing MRSA leaving large defect. Patient was stabilized, blood glucose optimized , IR optimized inflow to foot Hypertension,copd, a fib,pvd

Wound History: Patient presented with chronic ulcer hallux bone exposed and after amputation of the hallux necrotizing MRSA infection resulted in tissue defect full thickness. Patient optimized medically, nutritionally (jueven) IR optimized flow to foot and leg

Fish Skin Graft Applications: 5 applications 8 weeks

Patient Outcomes: patient in treatment for 5 weeks s/p hallux amputation

Initial presentation | Post debridement | Application of piscine acellular dermal matrix | week 6

CASE 3: 70 YEAR-OLD FEMALE LIMB SALVAGE

Patient History: 70 yo female referred by vascular after offered BKA as treatment for wound. Hypertension, DM, PVD, neuropathy, hyperchol.

Wound History: Patient refereed by IR after d/c from community hospital offered BKA as treatment .

Patient optimized medically and nutritionally (jueven), and inflow optimized by IR.

Fish Skin Graft Applications:26 weeks of treatment 4 applications of kerecis. (insurance issue forced d/c of treatment with PADM finished with acellular matrix (restrata)

Patient Outcomes: After 4 applications patient defect significantly epithelized with excellent structure coverage finished treatment with acellular matrix.

Initial presentation | Post debridement | Application of piscine acellular dermal matrix intraoperatively | Week 15 | Week 26 Follow up Increased granulation tissue to cover tendon