

A rare constellation of devastating injuries – open pelvic fracture with testicular disruption, a case report.

Margaret Rose MD, MS; Jamie Pham, BS; Kelly Champlin, DO; Saptarshi Biswas, MD, FACS

Background

- Open pelvic fracture is an uncommon injury with an extremely high mortality.
- Early mortality is related to exsanguinating hemorrhage and late with sepsis.
- Genitourinary tract injuries occur in 3-10% of trauma patients.
- Perineum and scrotal area injuries can occur due to motorcycle accidents; known as “fuel tank” or “straddle type” injuries in which the driver collides with a fixed object resulting in deceleration forces and blunt trauma.
- We present a case of a patient who sustained devastating polytrauma including open pelvic fracture and testicular rupture.

Case Description

- 40-year-old male presented as a level 1 trauma following a motorcycle accident
- He was intubated in the field and found to have an open pelvic fracture with testicular evisceration, bilateral pulseless open upper extremity fractures, and complex facial and extremity lacerations upon arrival.
- FAST exam was positive in the upper quadrants and pericardial window.
- Massive transfusion protocol was initiated for hemorrhagic shock, pelvic binder was placed, and the patient emergently underwent exploratory laparotomy.
- He was found to have left testicular rupture, urethral transection at the bladder neck, and intraperitoneal bladder rupture.
- He underwent repair of intraperitoneal bladder injury, suprapubic catheter placement, and left orchiectomy.
- The patient had a protracted ICU course with multi-organ failure, but eventually made a successful recovery.

Results

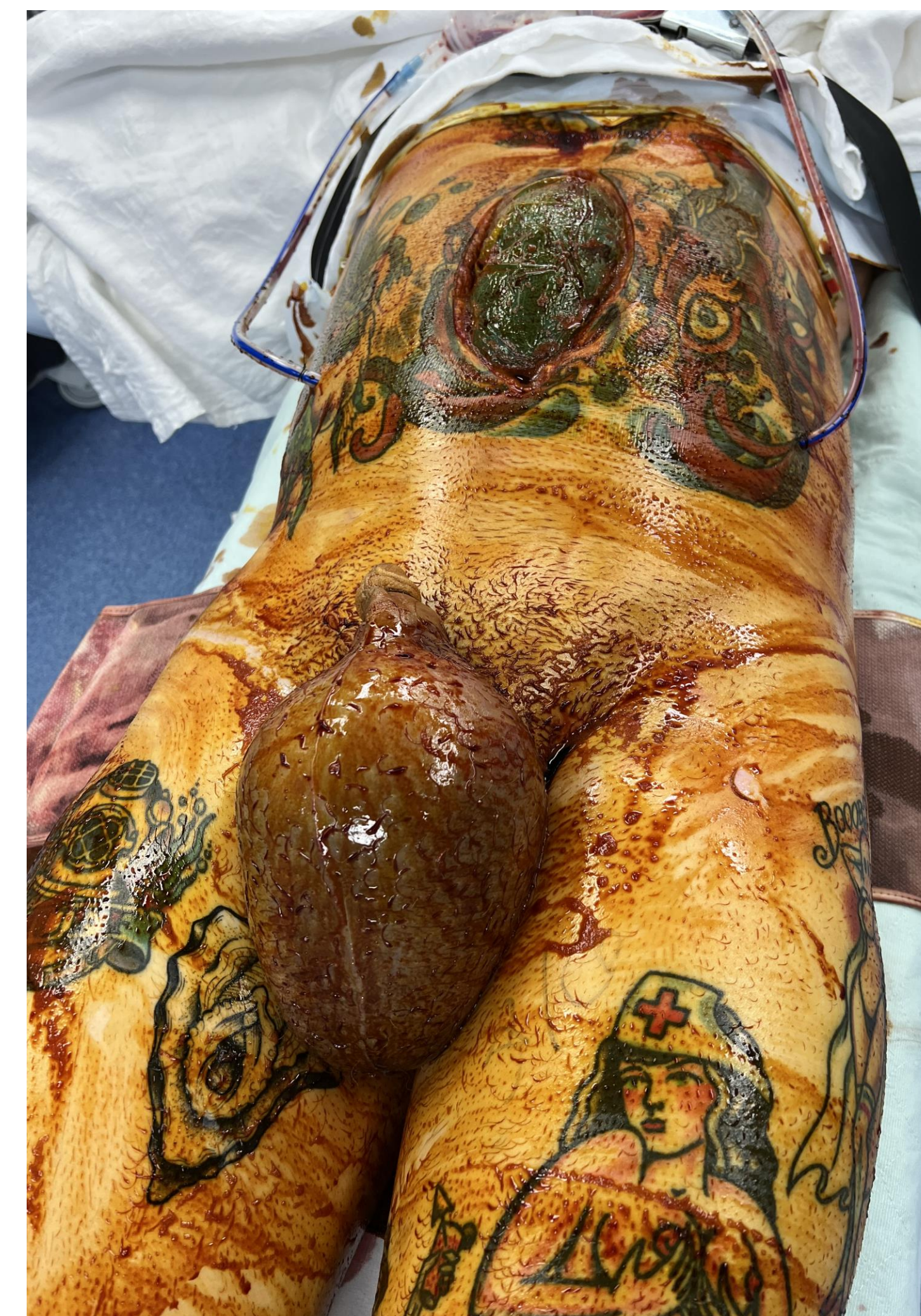
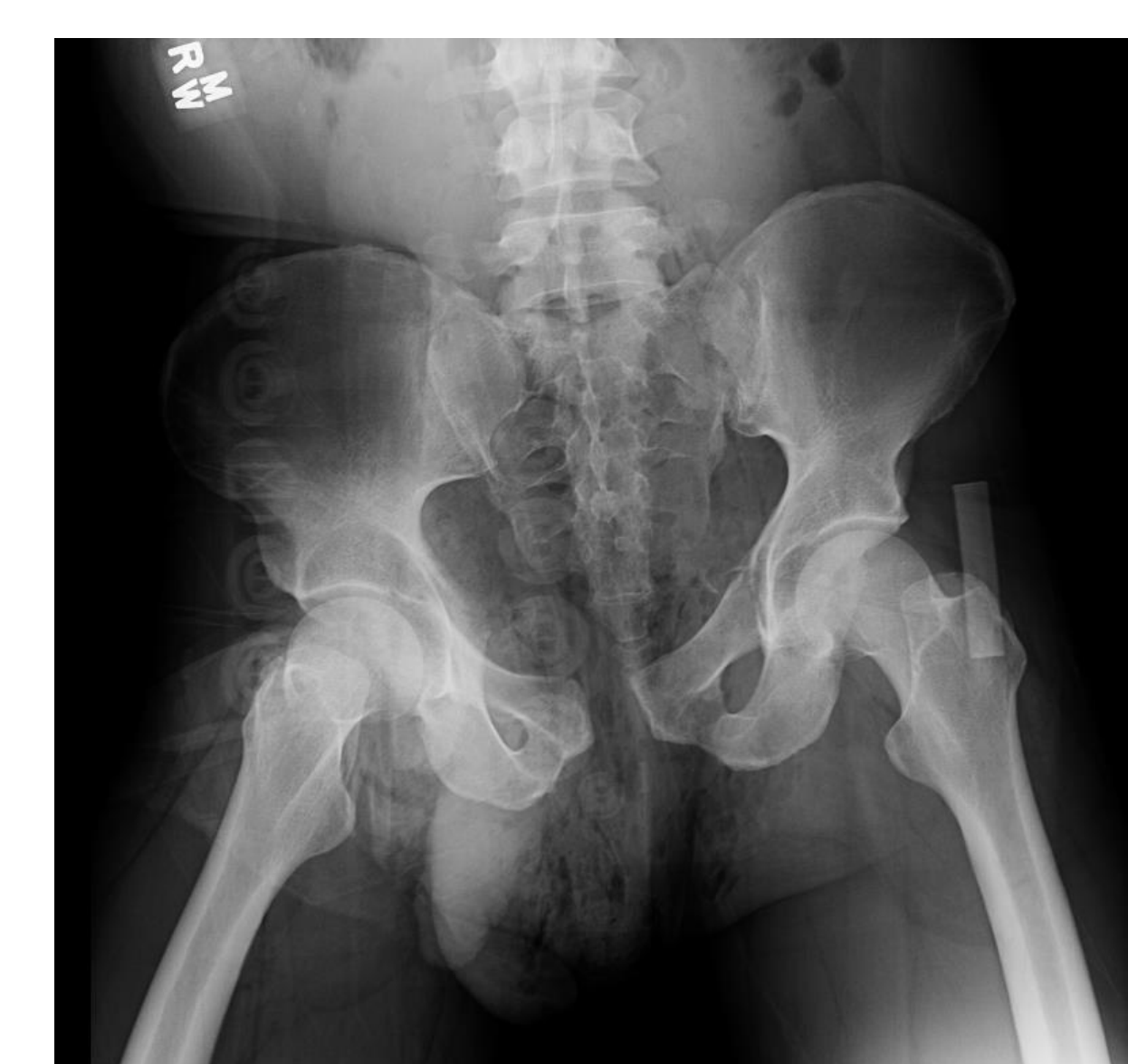
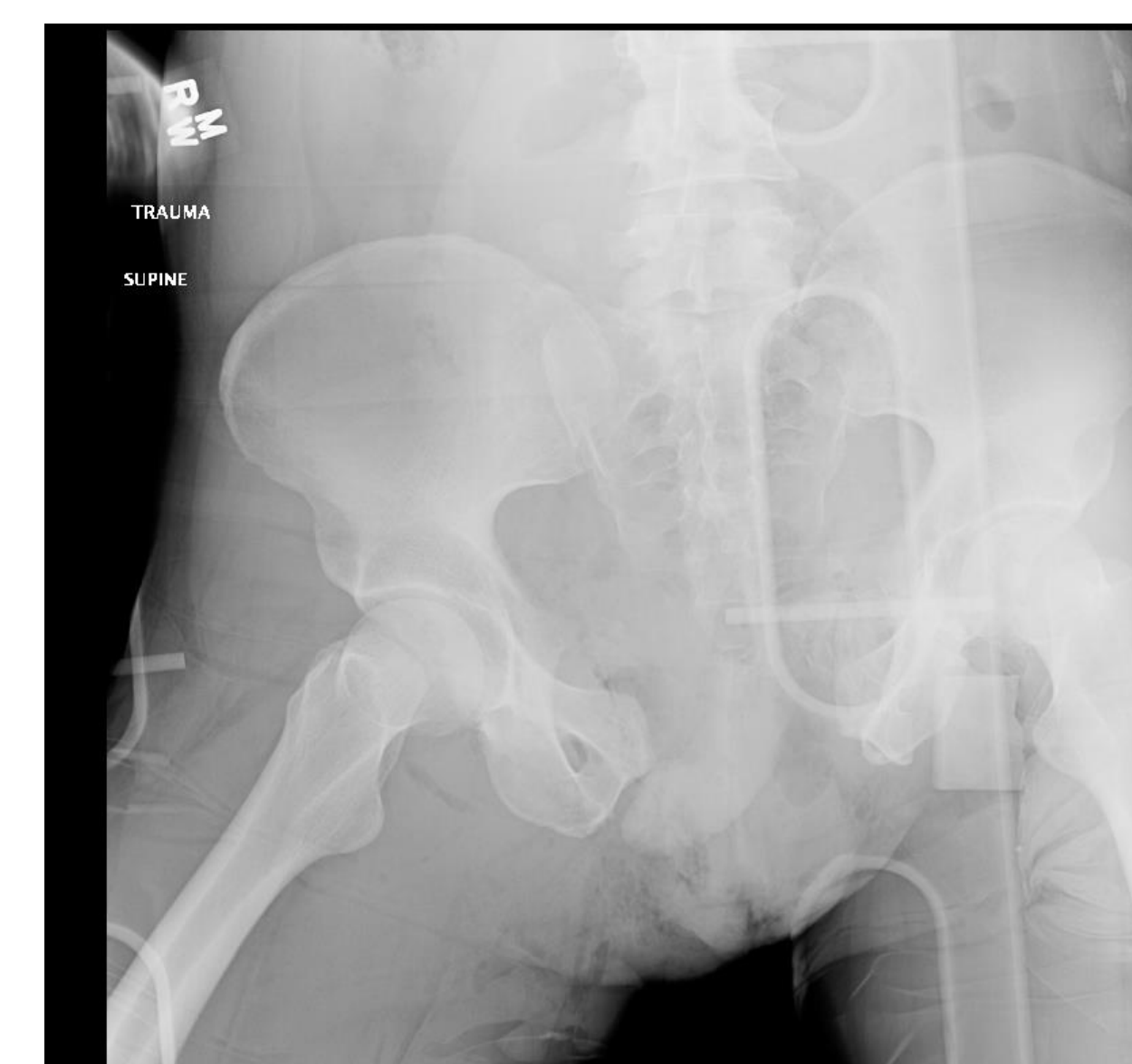
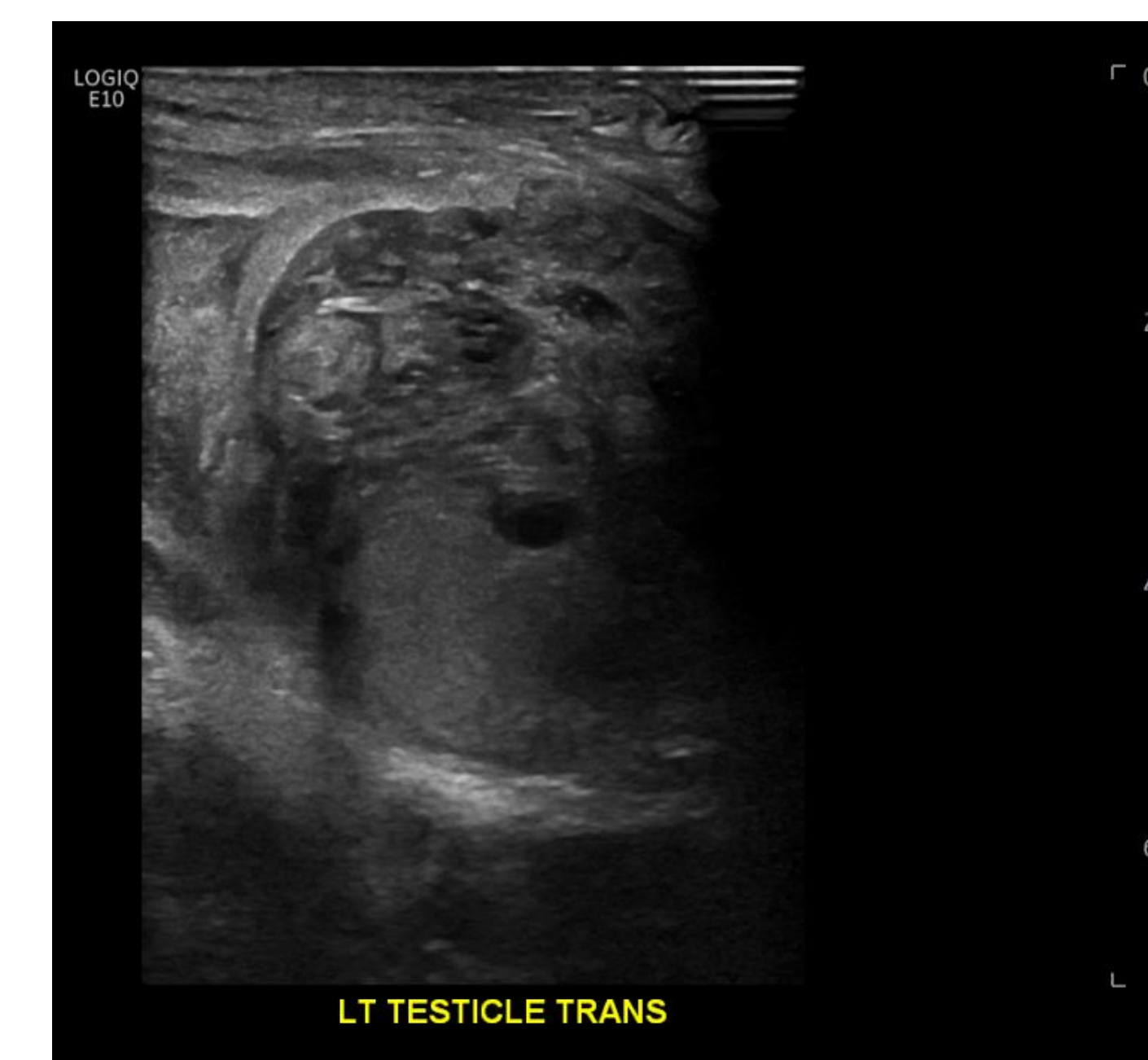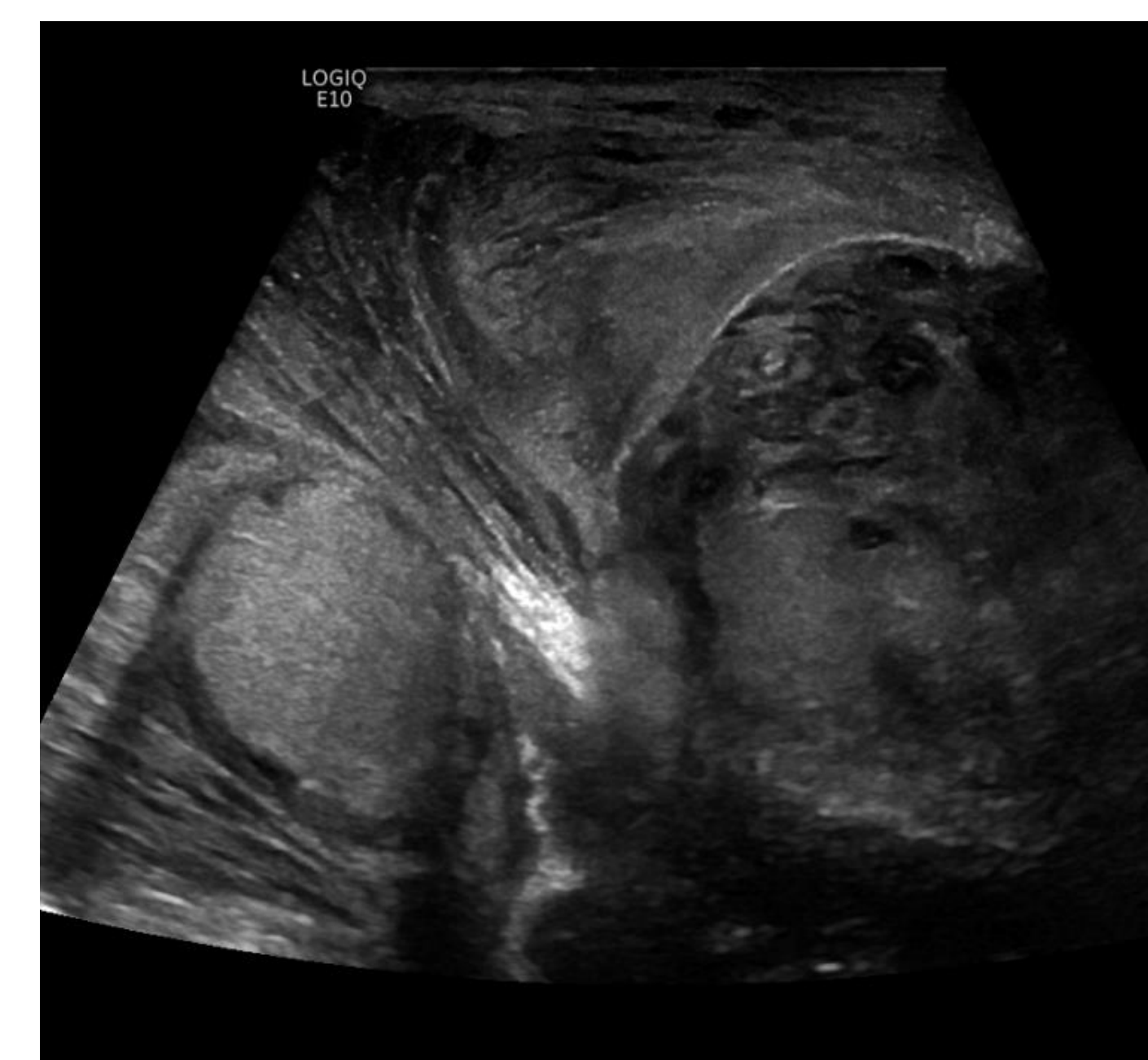Figure 1. Open pelvic fracture with testicular evisceration.



Figures 2 and 3. Portable pelvis x-rays obtained in the trauma bay. Open book pelvic fracture with open component. 7 cm diastasis of pubic symphysis. Fracture of left sacral ala. Diastasis improved to 2.2 cm in figure on the right.



Figures 4 and 5. Testicular Ultrasound. The right testicle measures 2.7 x 3.2 x 4.5 cm, with normal margination and echogenicity. The left testicle measures 2.5 x 2.3 x 2.5 cm, with irregular poorly delineated margination and a large region of heterogeneous echogenicity adjacently which is suspicious for extruded testicular tissue, possibly related to rupture.

Discussion

- Open pelvic fracture is a devastating injury not only because of the high mortality rate during the trauma, but also due to increased incidence rate of infection during the subsequent hospital course.
- The colonized bacteria may originate from contamination by the environment or more likely due to presence of fecal content in the retroperitoneal cavity.
- Faringer et al reported the infection rates in relation to open wounds and classified them into zones I, II and III.
- Testicular rupture occurs when the tunica albuginea is torn, resulting in testicular parenchyma extrusion.
- Testicular rupture may present clinically with scrotal swelling, hematocele, ecchymosis, tenderness, and loss of contours.
- Prompt diagnosis and early surgical intervention is crucial in preventing future complications of impaired fertility, chronic pain, hypogonadism, delayed orchiectomy, testicular atrophy, and altered self-image.

Conclusion

- Pelvic ring fractures with genitourinary injuries were associated with a higher rate of intensive care unit admission and longer hospital stays.
- Attention should be paid in ruling out testicular injuries in unstable pelvic ring disruptions.
- Limited literature exists on incidence and outcomes, but multidisciplinary approach is pivotal to maximizing outcomes in these devastating injuries.

References

References available upon request.