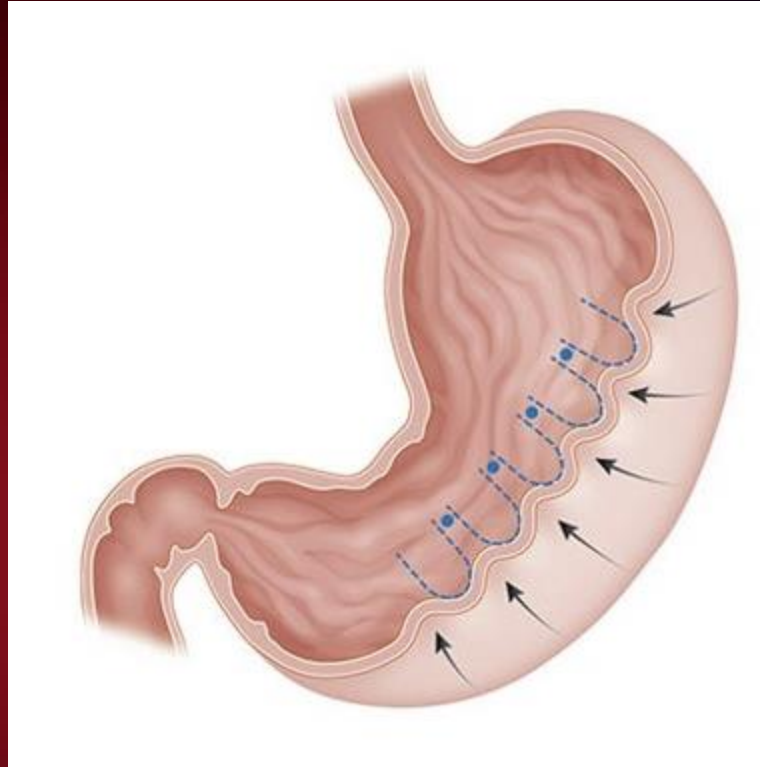


Endoscopic Sleeve Gastroplasty Leading to Gastric Ischemia and Perforation

- Plication of greater curve with endoscopic suture or stapler.
- Outpatient weight loss procedure



- ESG complications:
 - Transgastric sutures
 - Gastric ischemia
- Operative Repair:
 - Laparotomy, reversal of gastroplasty, ABthera wound vacuum
 - Planned re-open recent laparotomy